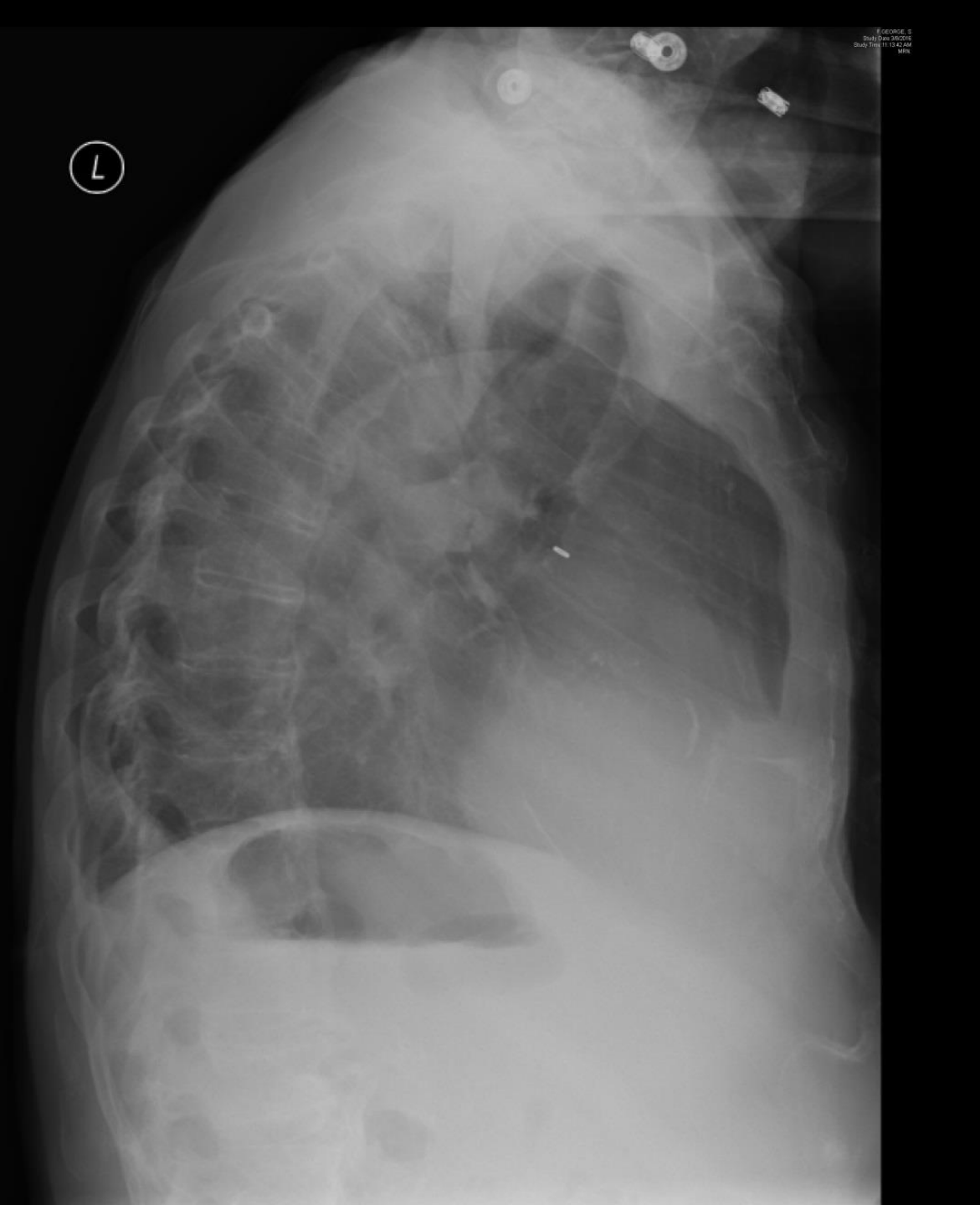
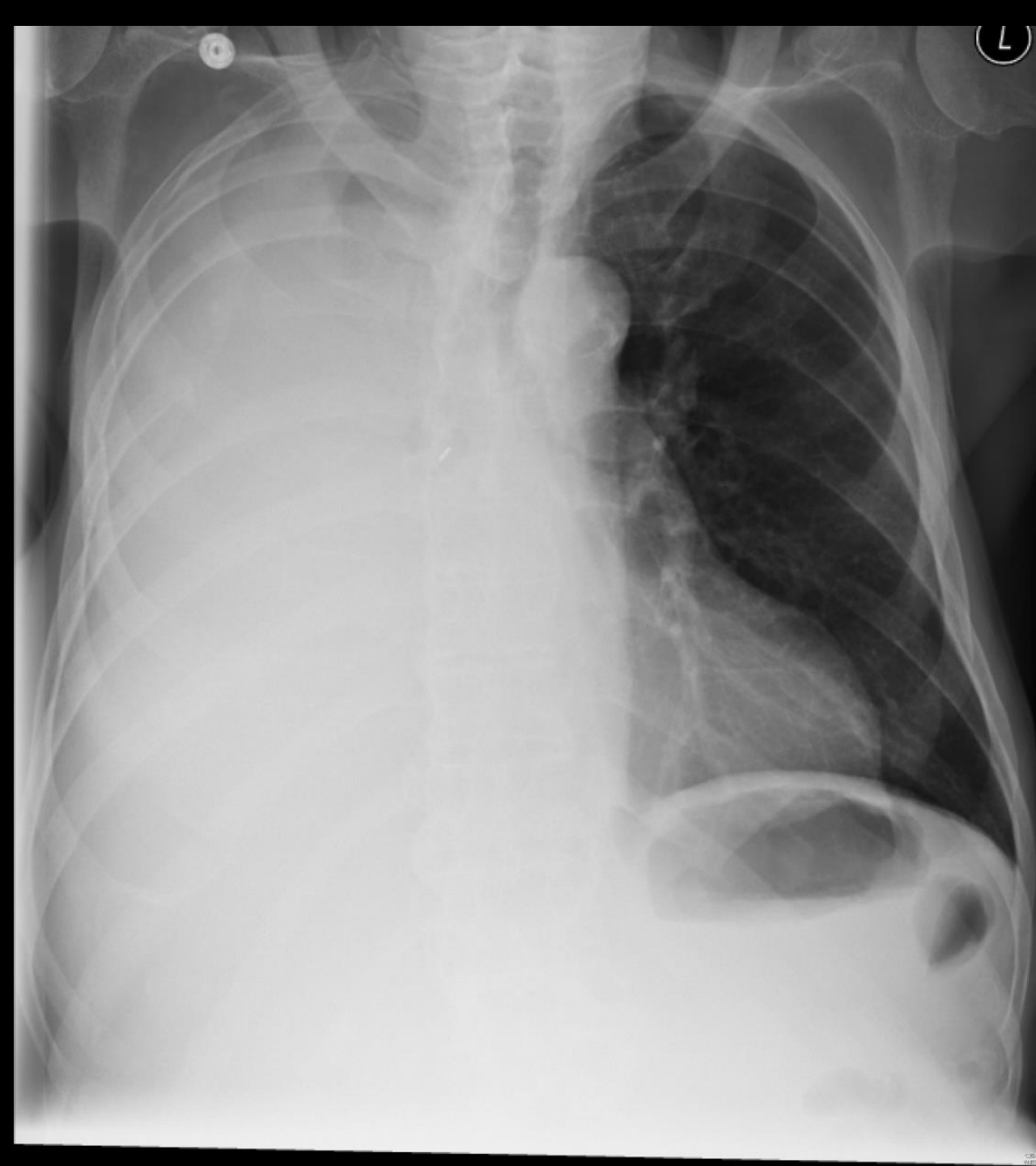

A Real Case

- 81 y.o. man w/ NASH cirrhosis p/w worsening SOB/fatigue x 1 week).
- Found to have hepatic hydrothorax
- NSTEMI in house -> BMS to RCA -> ASA + plavix



03/15/16 01:56:10PM ADM

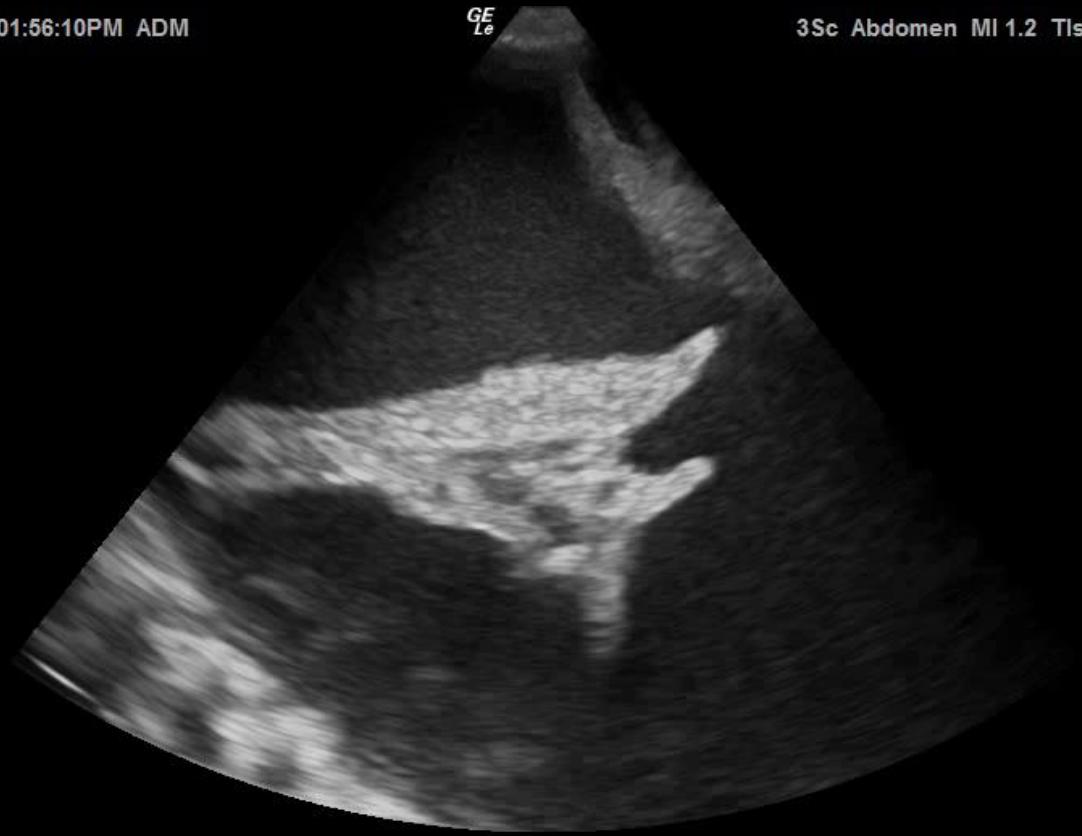GE
Le

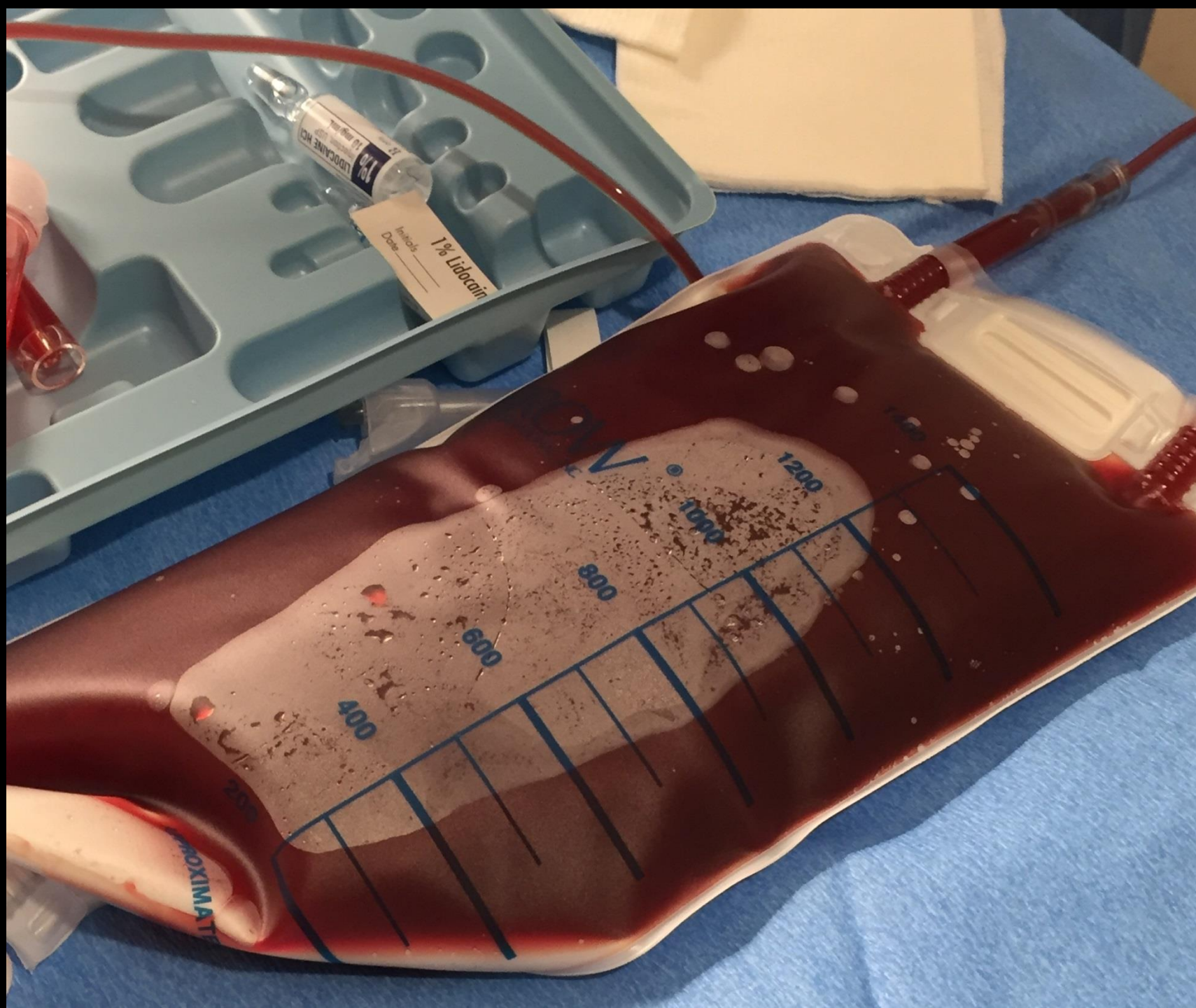
3Sc Abdomen MI 1.2 TIs 0.4

0-

10M

20-

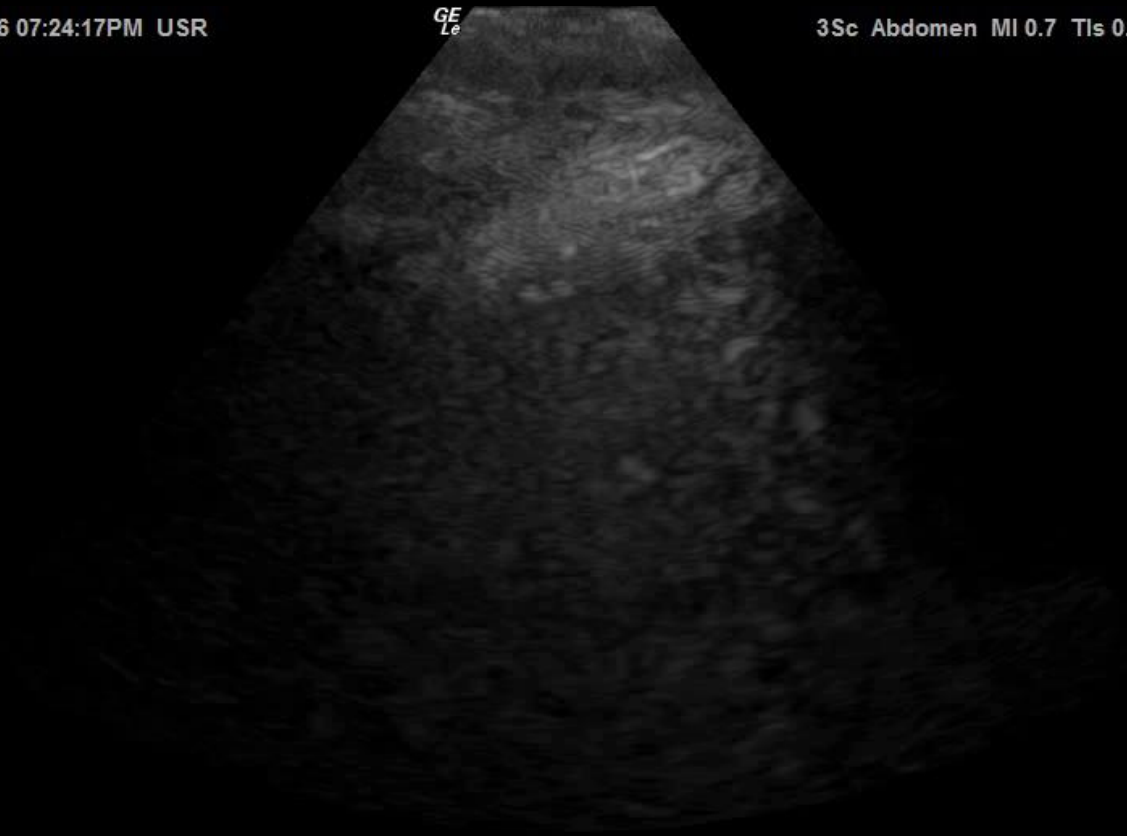



03/16/16 07:24:17PM USR

GE
Le

3Sc Abdomen MI 0.7 TIs 0.1



2-

4-



03/16/16 07:36:42PM USR

GE
L_e

3Sc Abdomen MI 0.7 TIs 0.1

0-

-

-

-

2-

-

4-

-

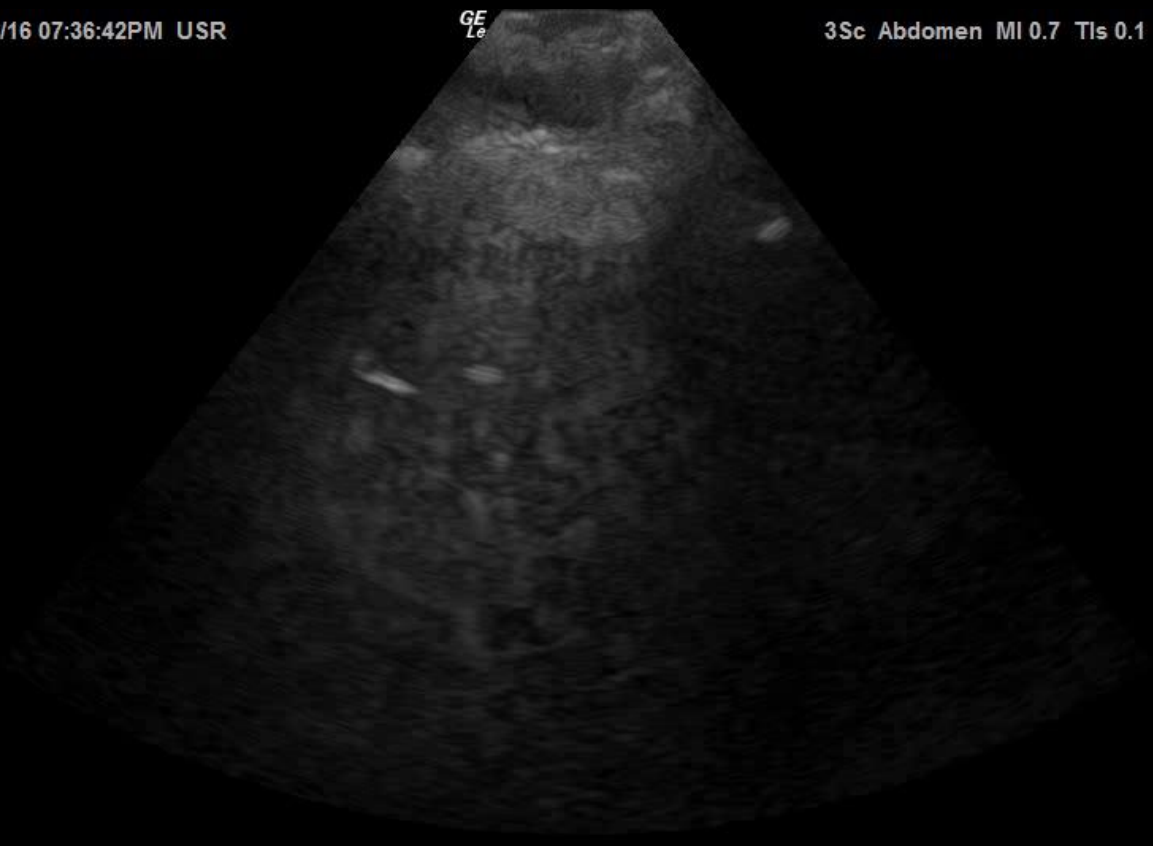4-

-

-

-

6-



03/16/16 07:35:39PM USR

GE
Le

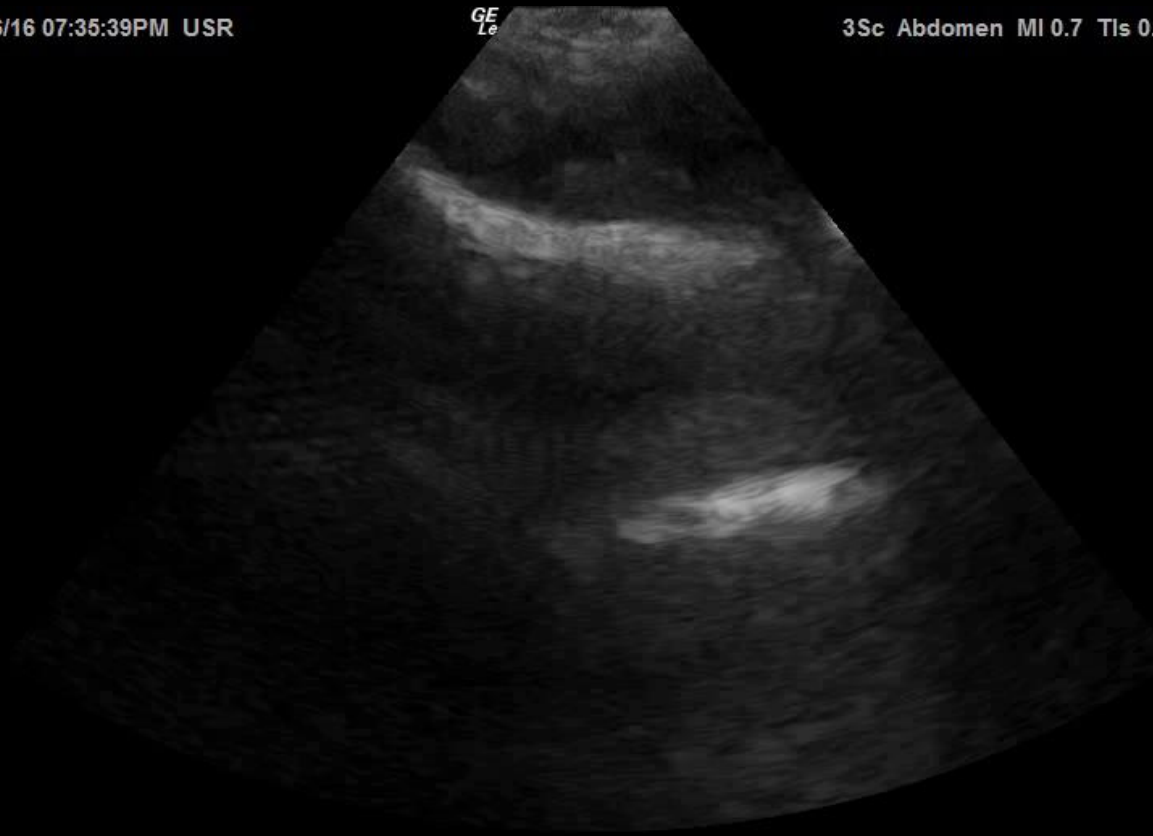3Sc Abdomen MI 0.7 TIs 0.1

0-

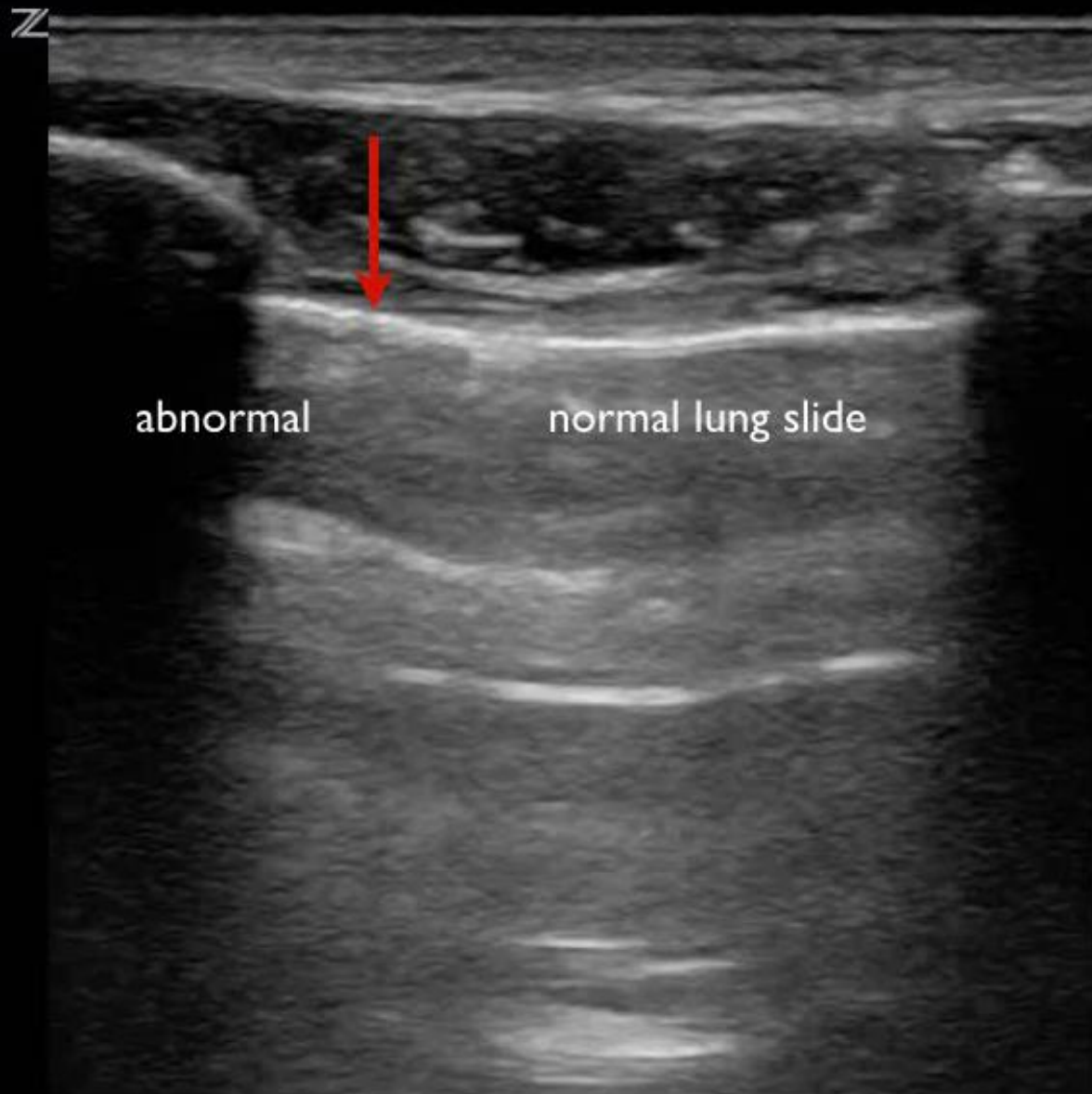
2-

4-

6-

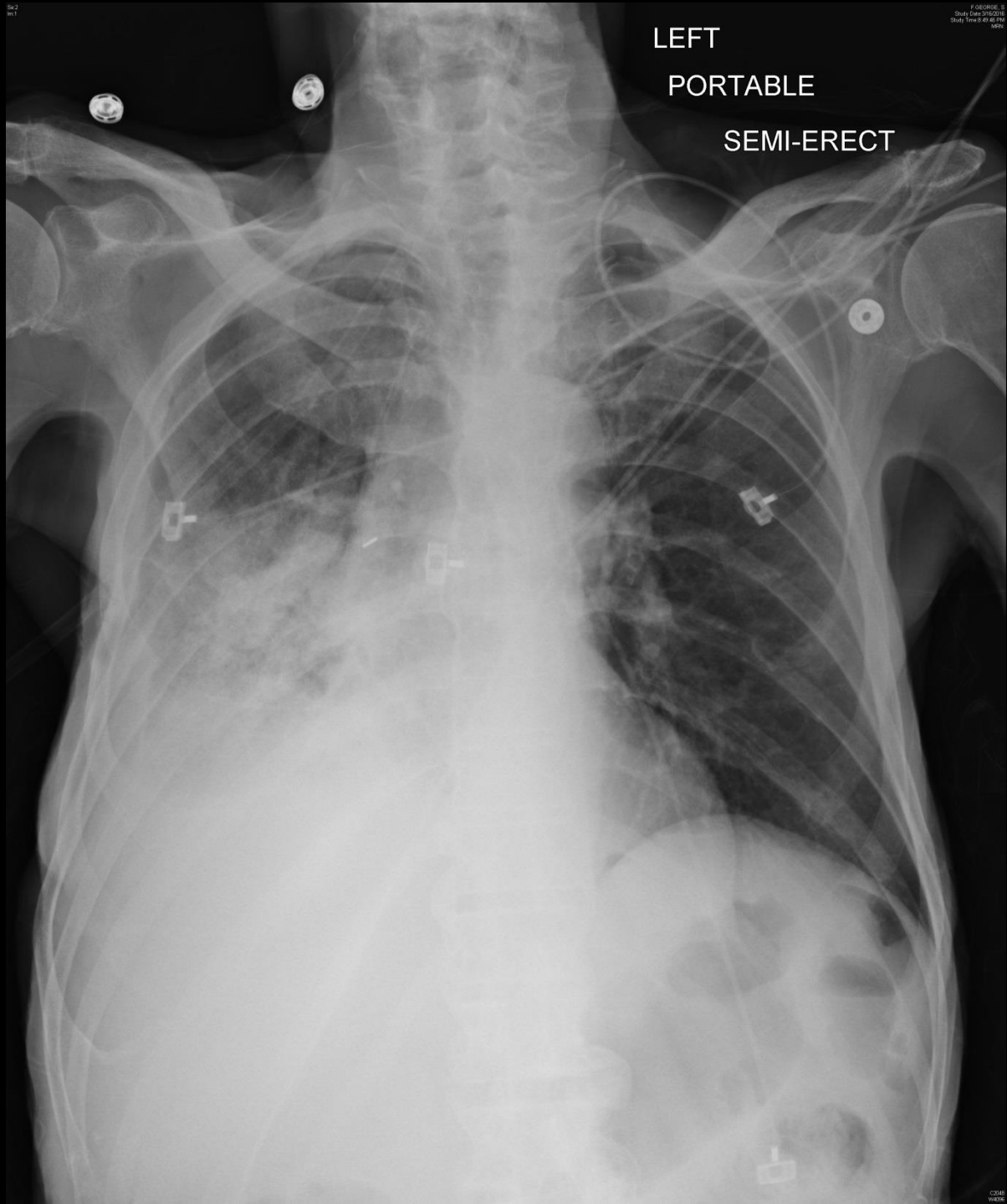


Lung Point



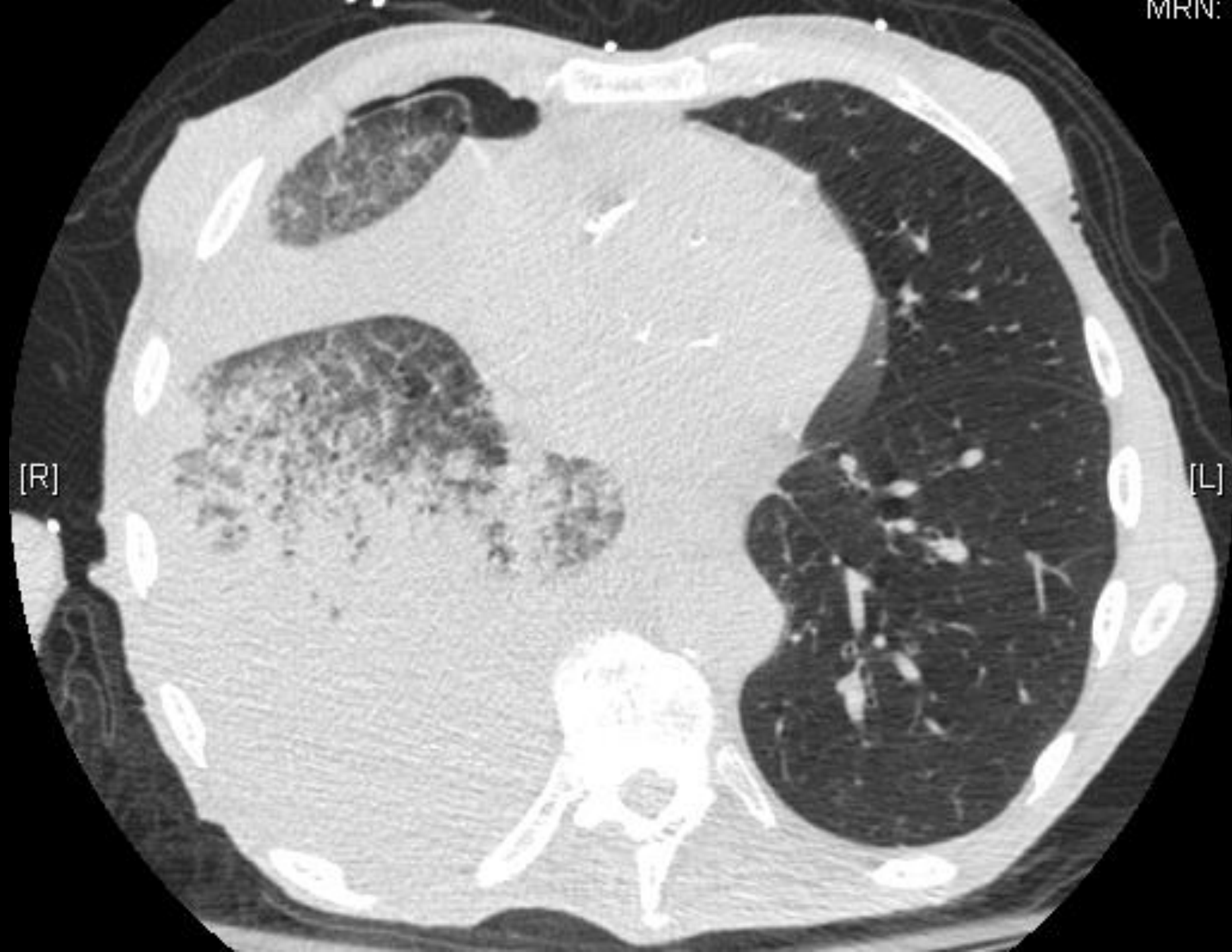
REBELEM

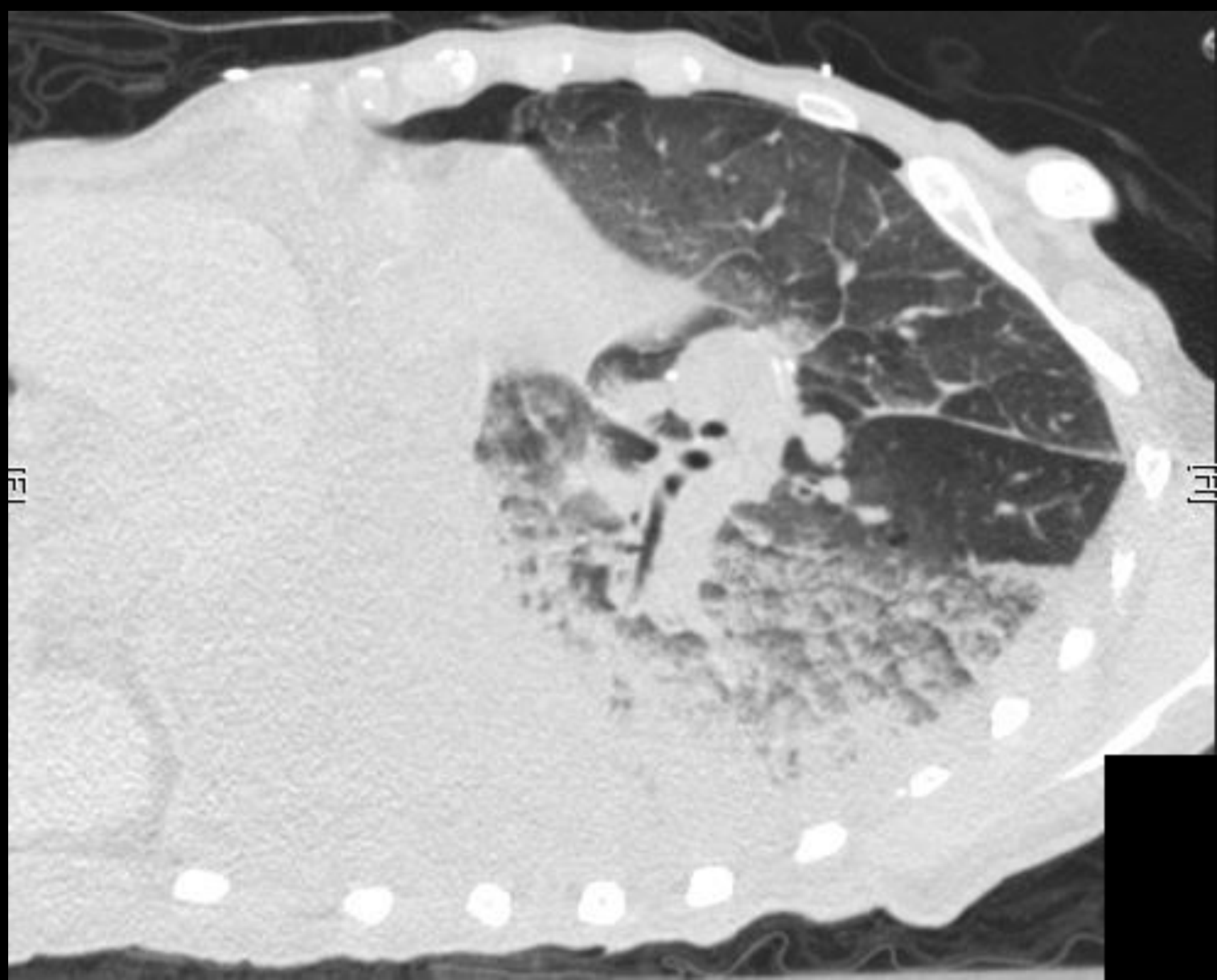
LEFT
PORTABLE
SEMI-ERECT



P. GEORGE, S
DR. GEORGE, S
Study Time: 4:40:10 PM
10/11/11

CR
WAVE



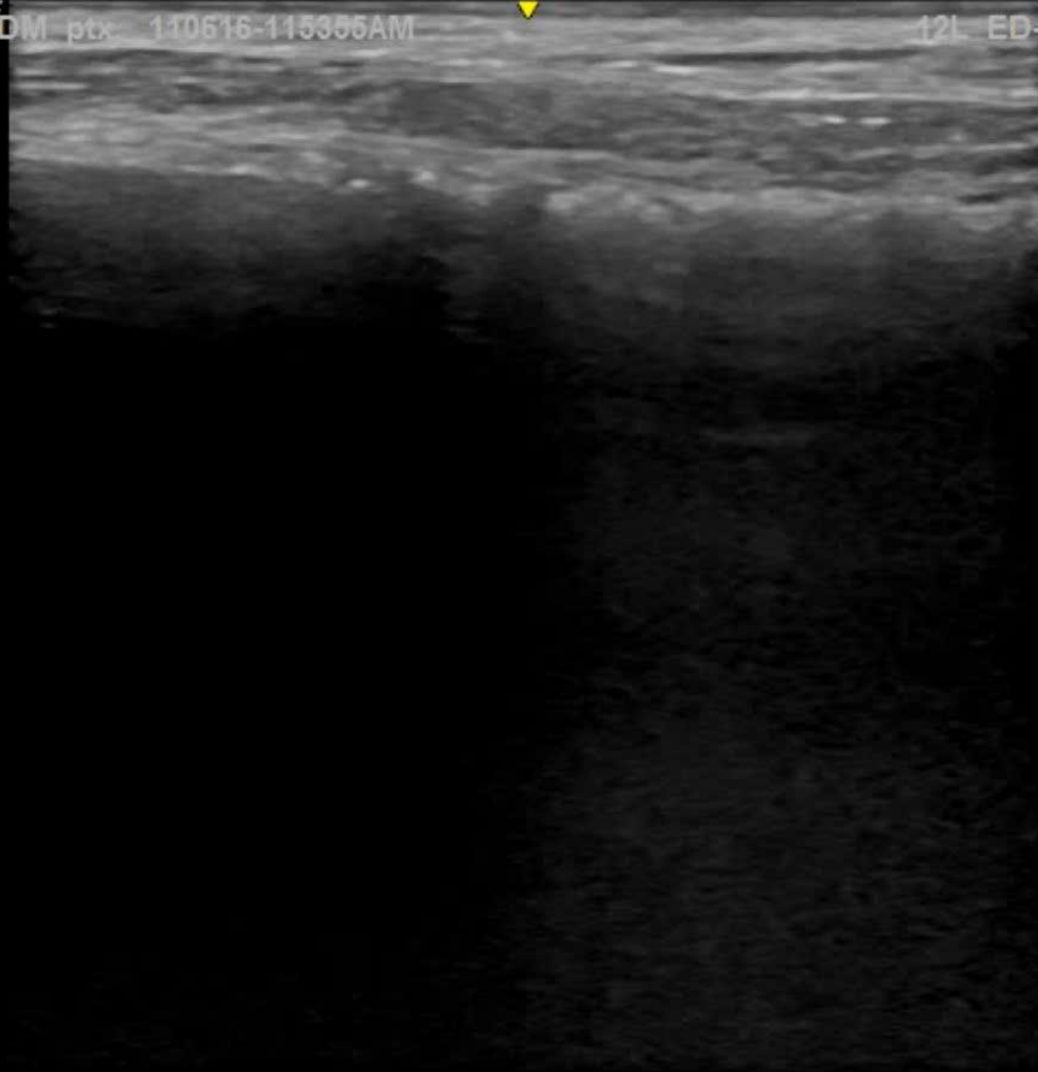


An (Almost) Real Case

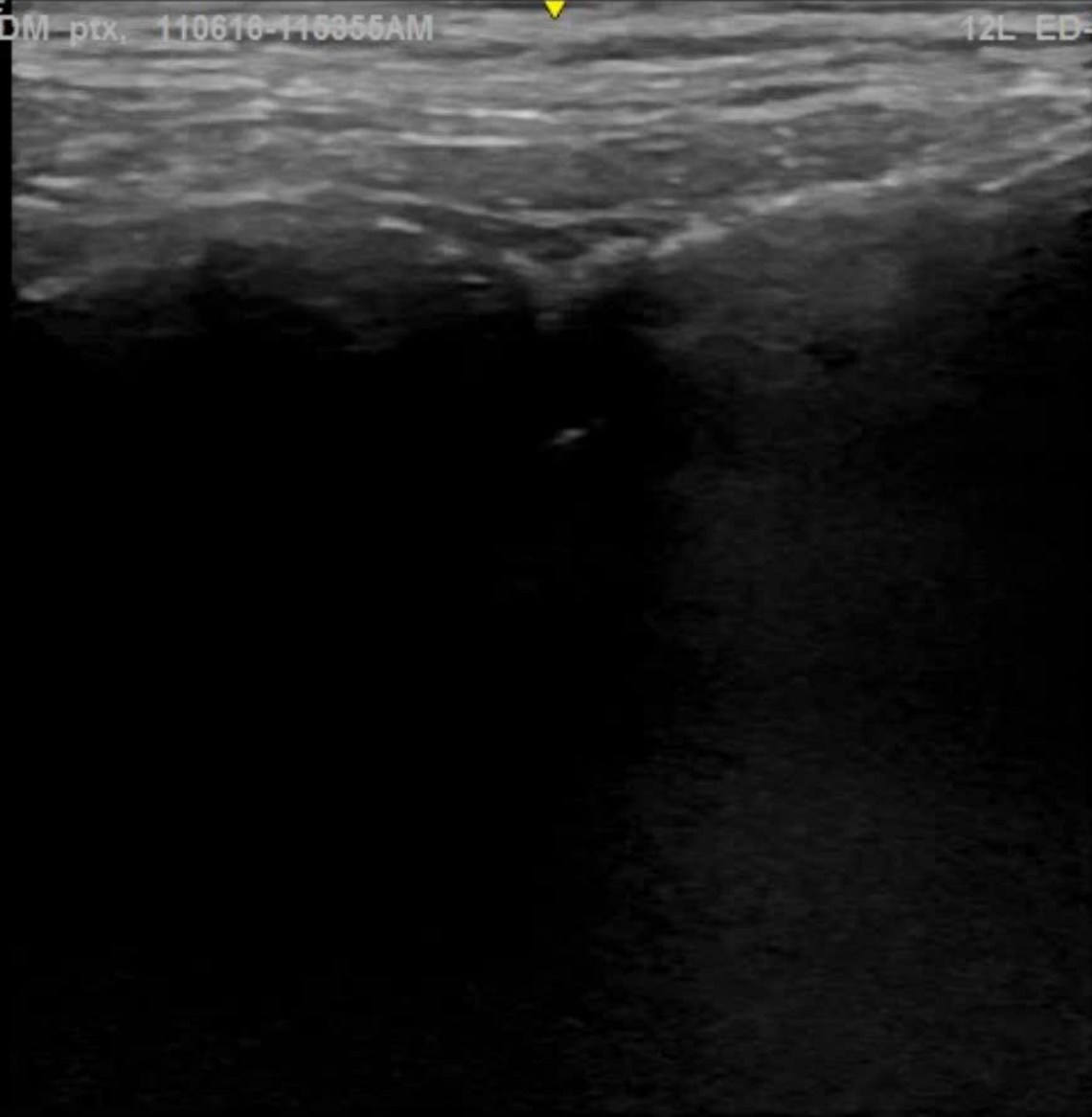
- 77 y.o. woman w/ h/o COPD, mild dementia, p/w acute onset SOB 1d PTA.
- Per EMS: O2 sat 80% on RA, 98% on 6L NC, HR 106, 147/89, afebrile
- No cough, fever, increase in sputum production
- Exam: decreased BS b/l. no wheezes.
- Lung US on the Right - normal

11/06/16 12:00:17PM GE ADM pt: 110616-115305AM
left uppr cw

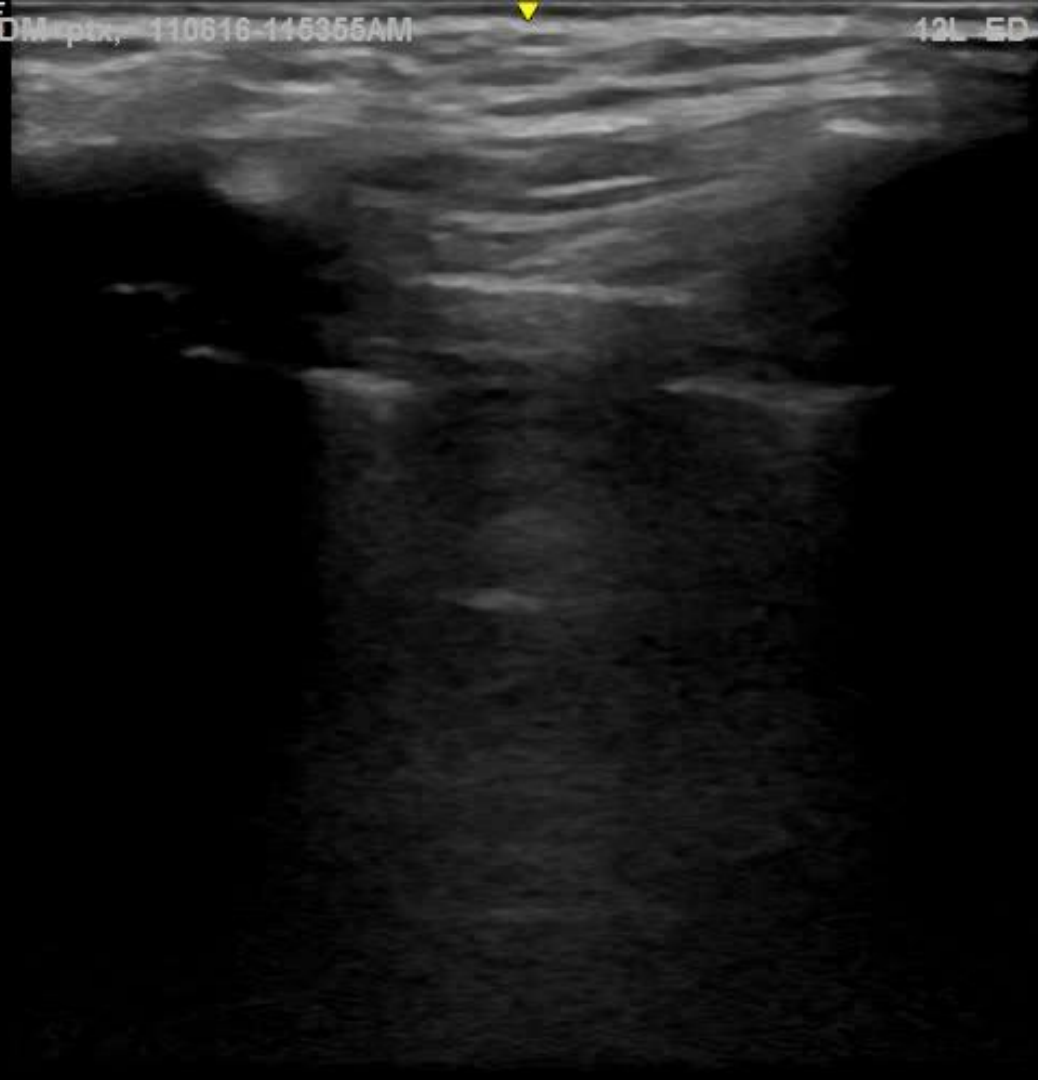
12L ED-VA MI 1.2 TIs 0.4



1-
2-
3-
4-



1-
-
-
-
II
-
-
3-
-
-
4-



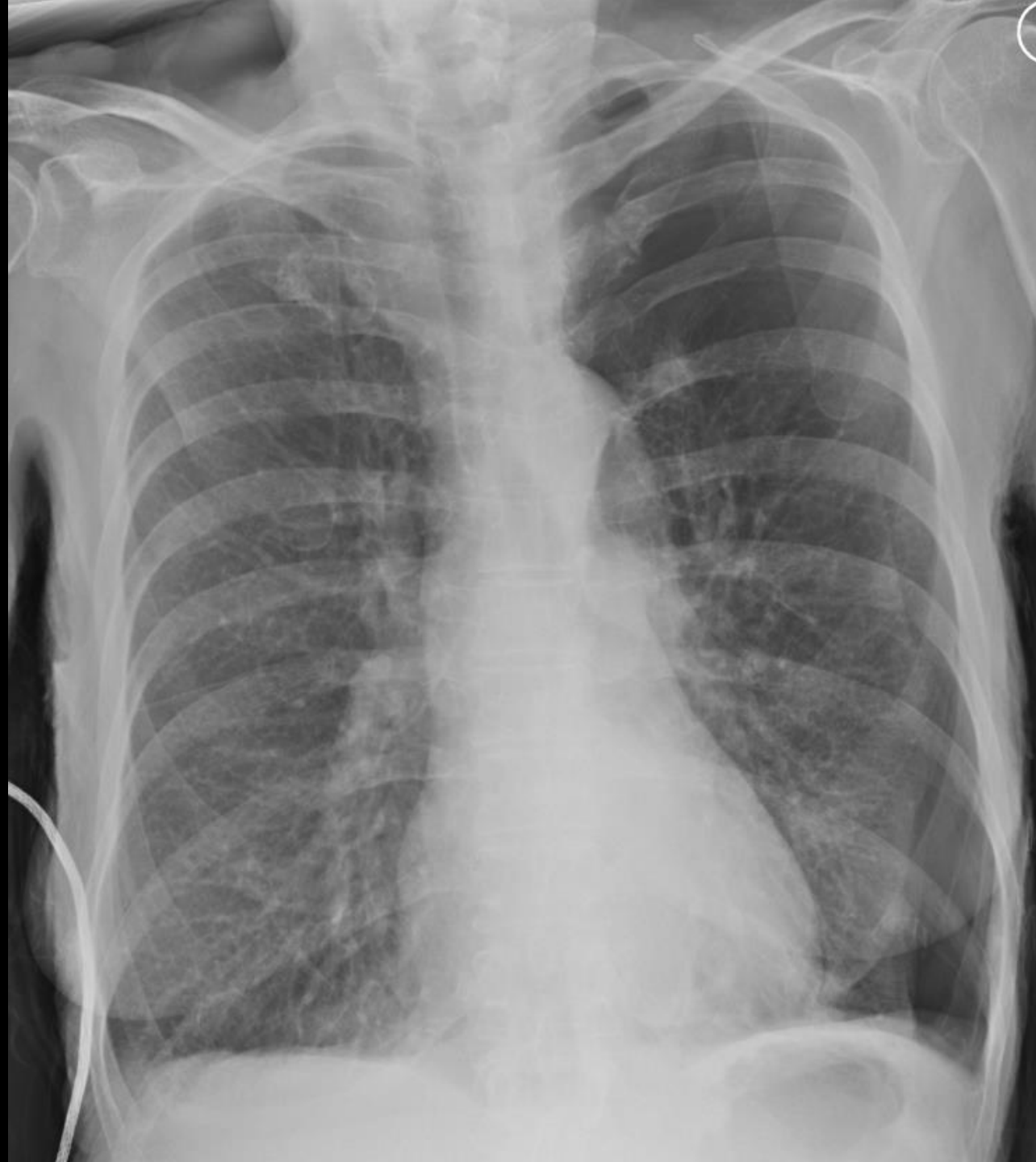1-

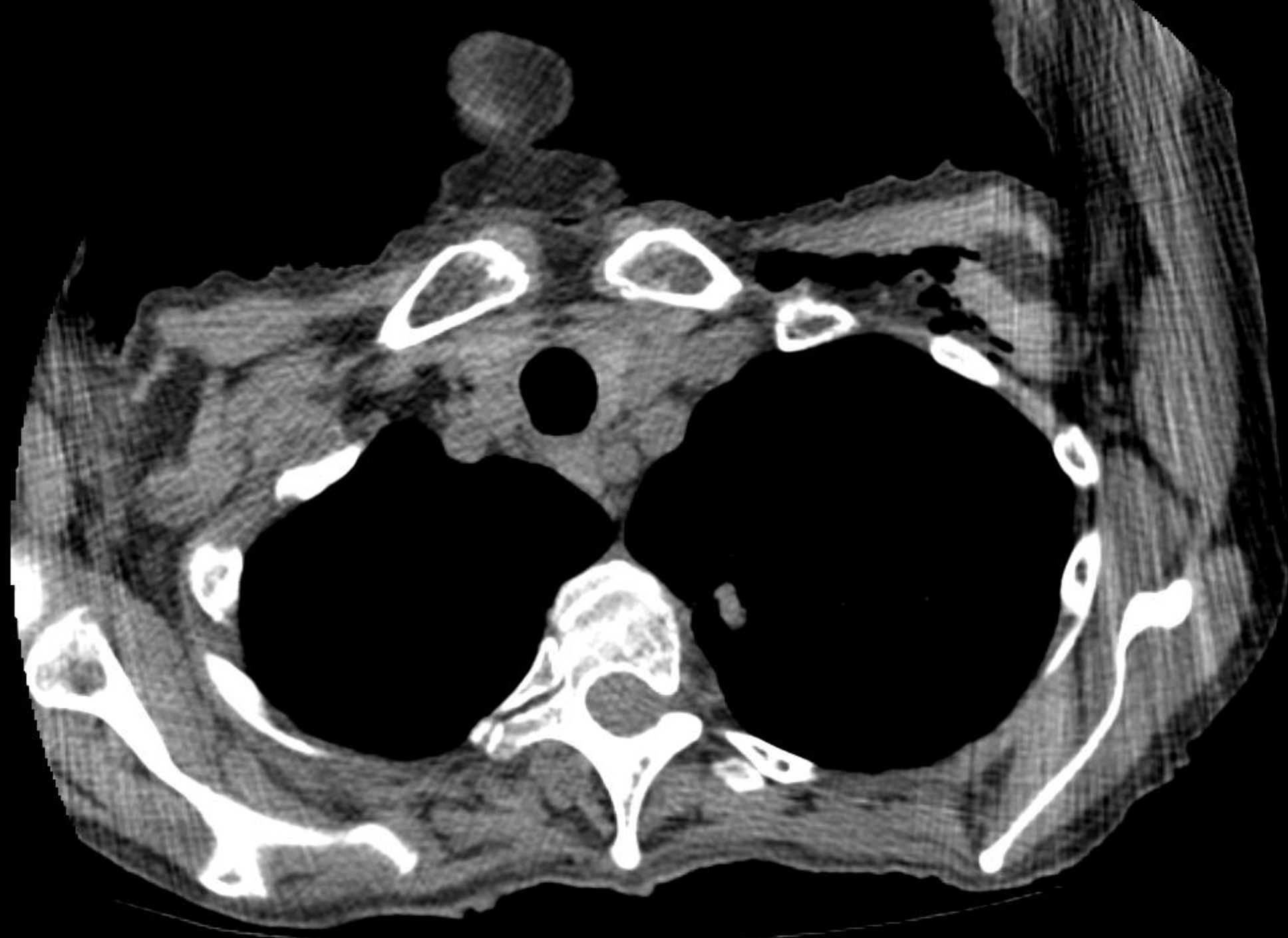II

3-

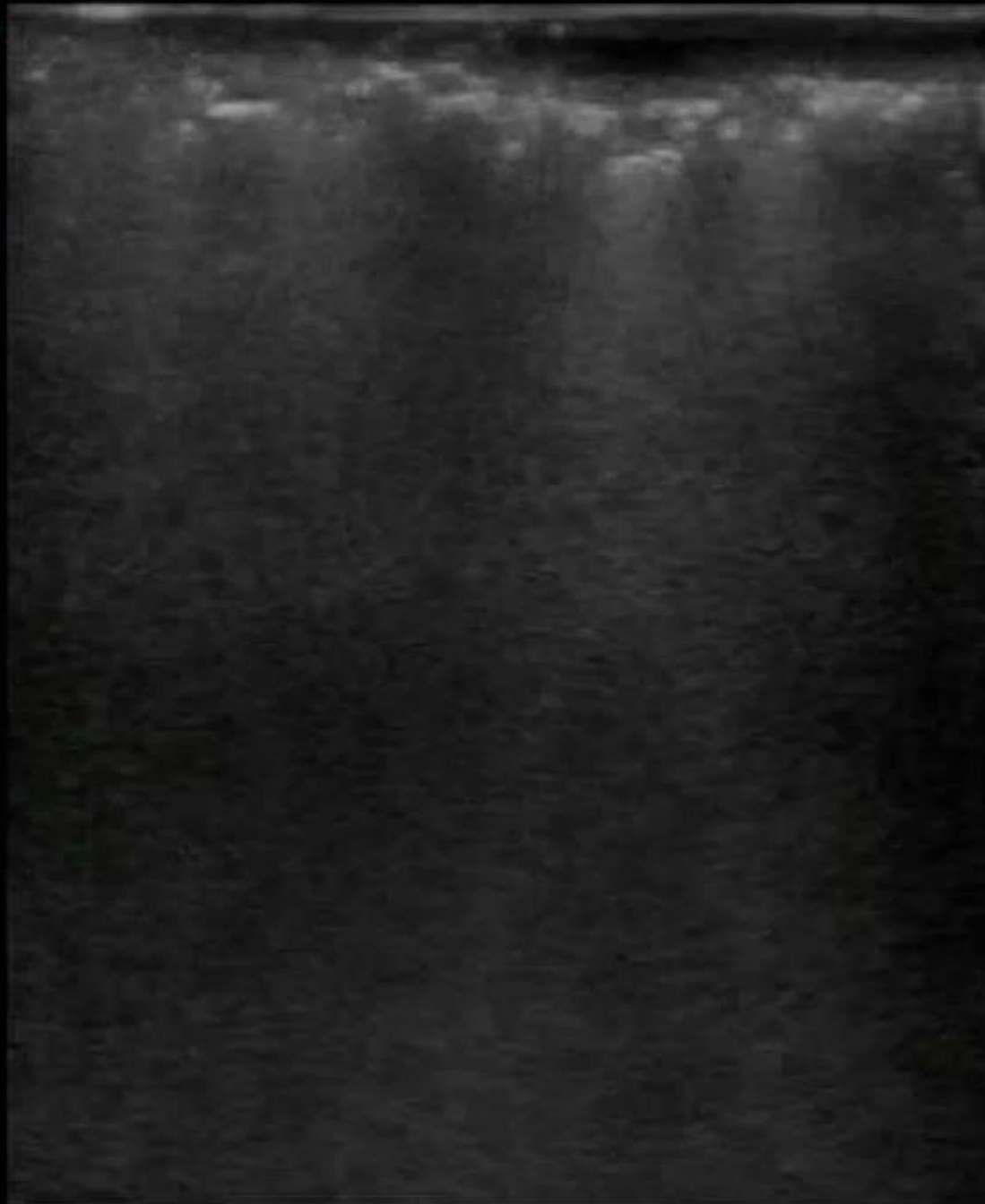
4-







L GROIN



4.7