

# POCUS Case Conference

10-25-2018

Gregory Mints

# Case Presentation

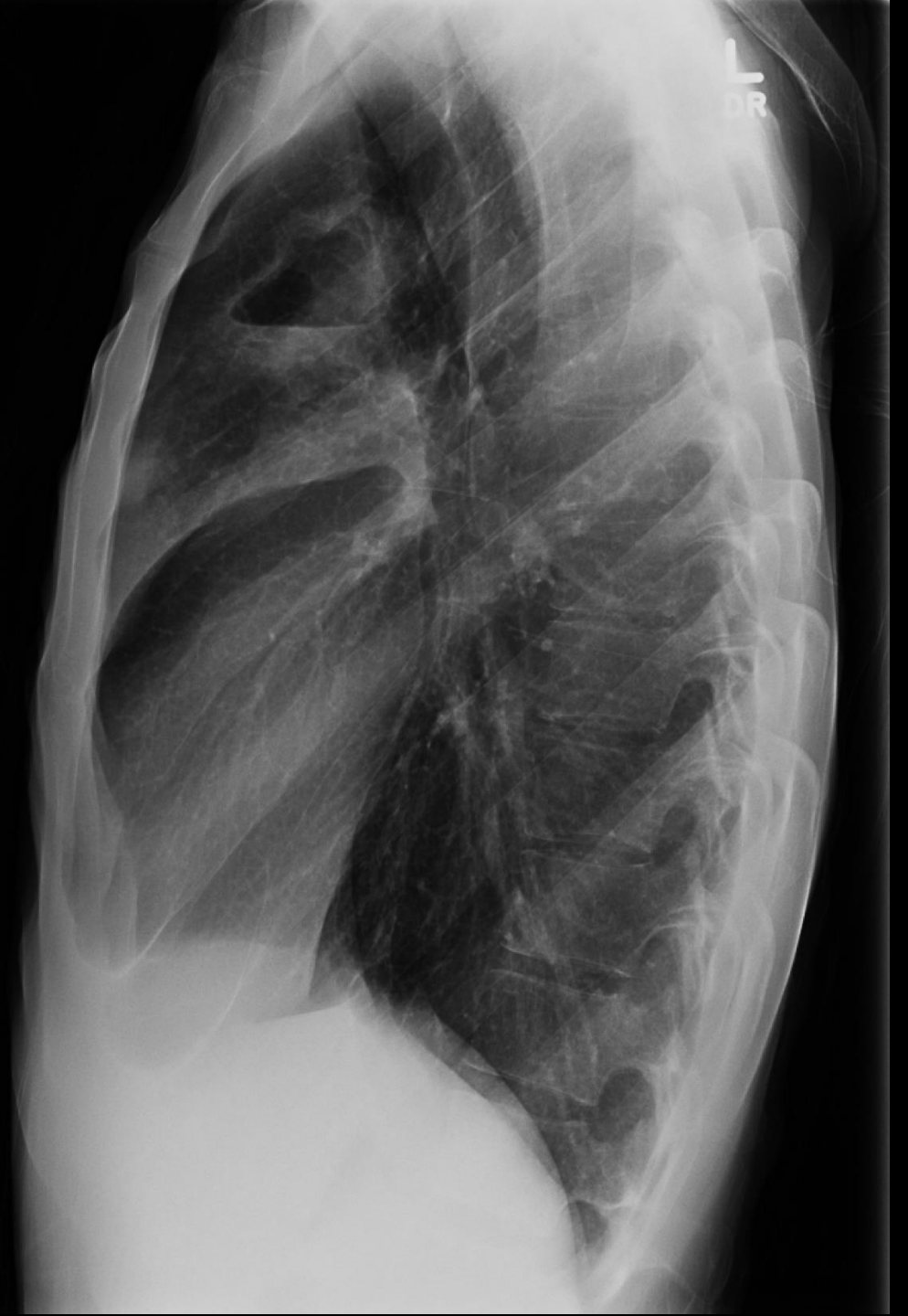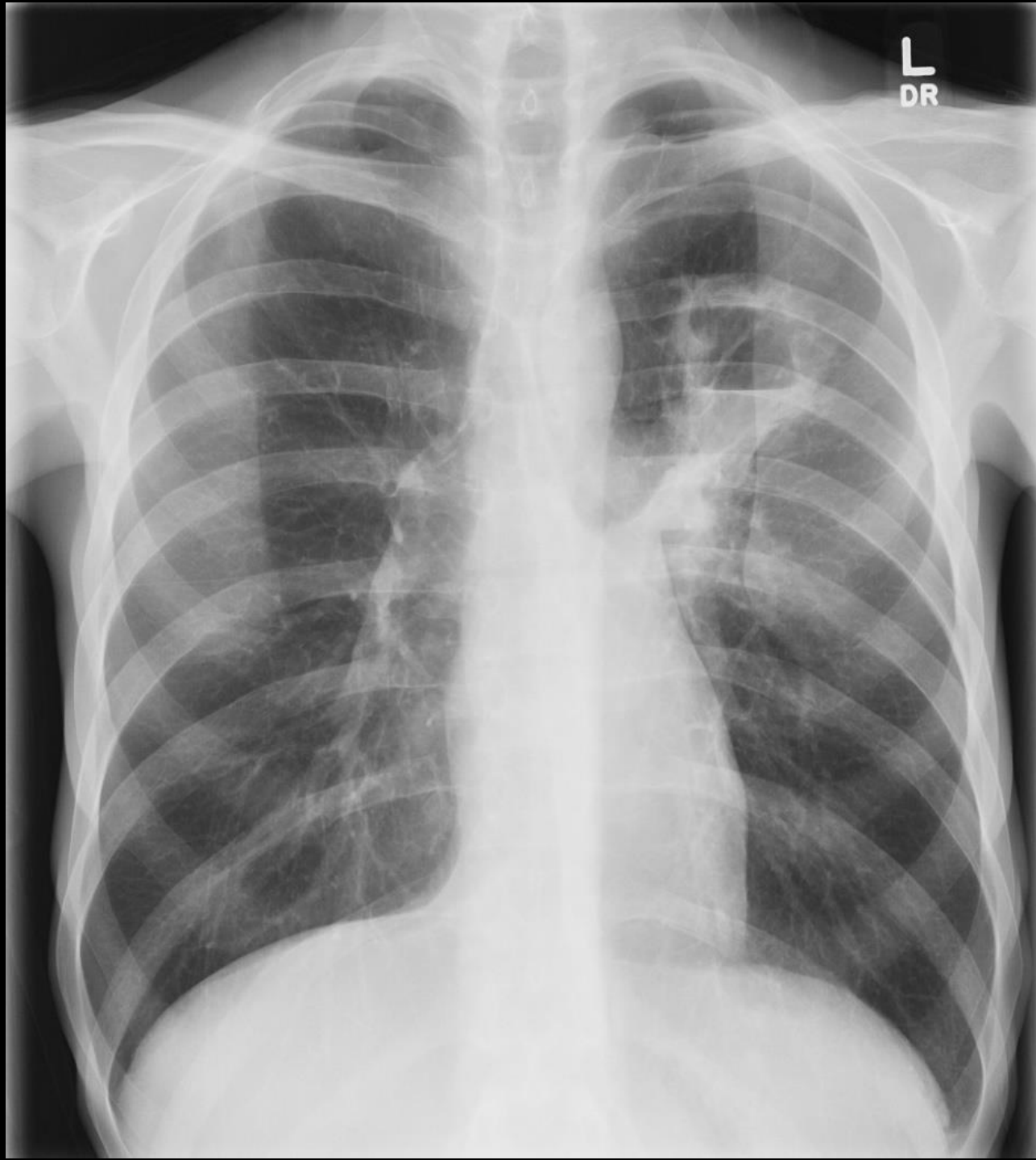- 28 y.o. man w/ h/o asthma, recurrent pneumonia sent by PMD for evaluation of progressive weight loss and concern for eating disorder.
- Patient reports weight loss over past 4 years: 170 -> 109lbs.
- Played football as a QB in high school. Denies use of steroids or any other illicit supplements. + h/o concussions.
- Moved to NYC from SC 8 years prior to pursue vigorous religious studies. Lived in a Yeshiva dorm.
- Prior work up: normal TSH, BMP, CBC, transglutaminase Ab (-)
- Recently married. Wife in the 1<sup>st</sup> trimester of pregnancy.

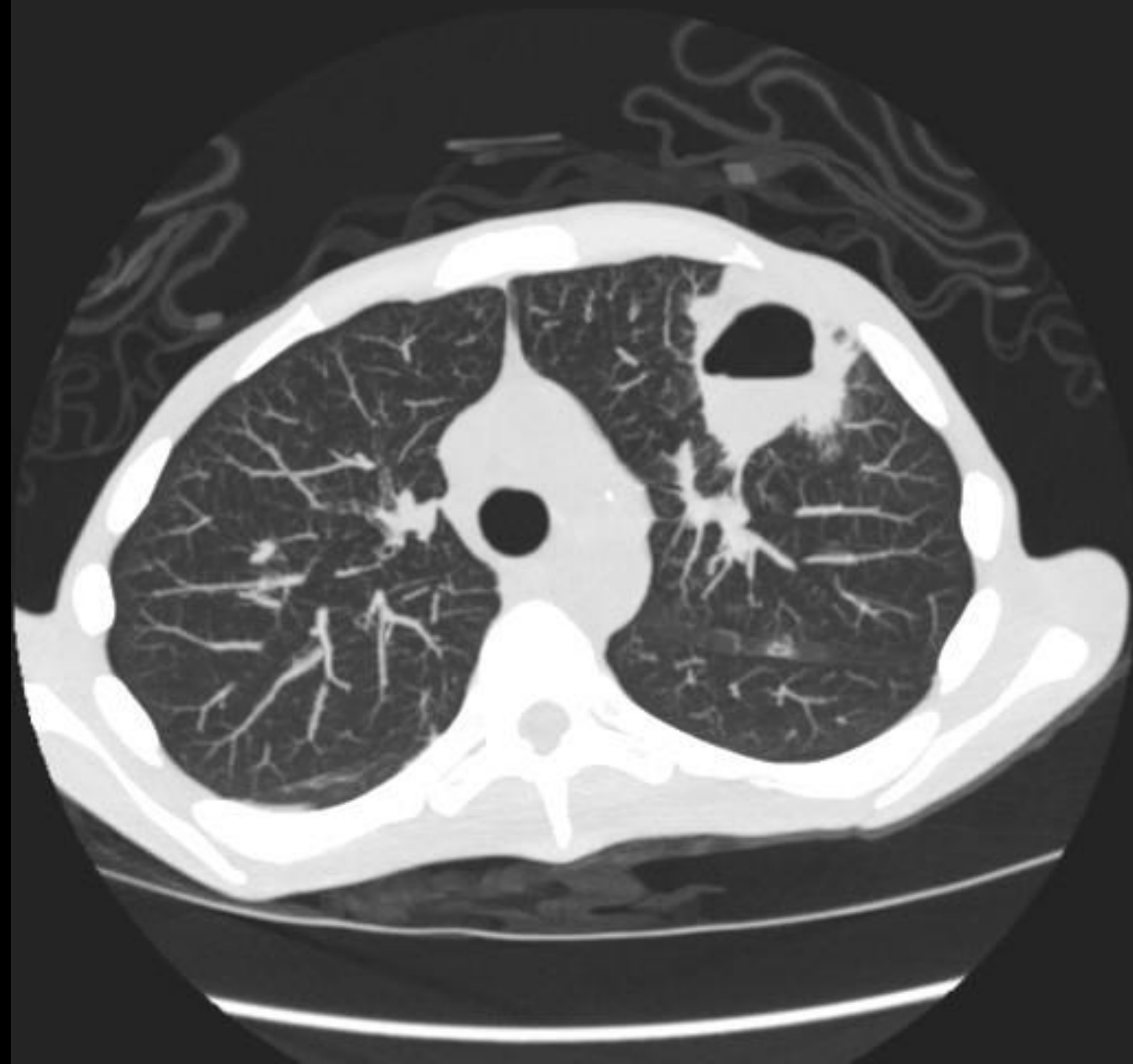
# Case Presentation

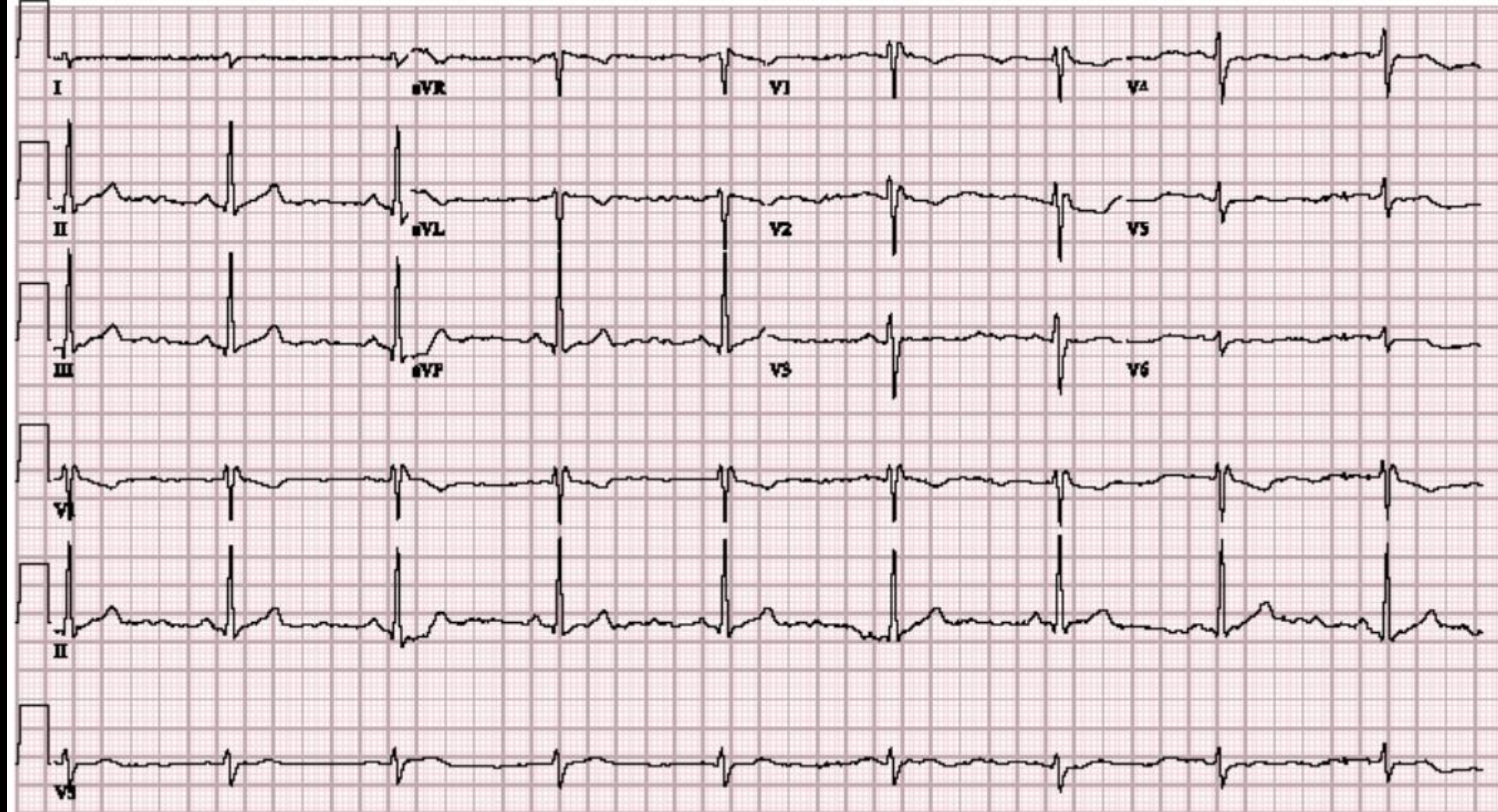
- BMI 14
- Decreased Lung sounds L anteriorly
- 97/65, 65, 12, 36.6, 98% RA
- Elevated JVP
- No edema, no M/R/G
- Otherwise unremarkable exam

# Labs

- WBC 6.8
- BUN/Cr = 35/0.7
- Alb 2.2







09/10/18 04:47:05PM ADM 091018-041659PM

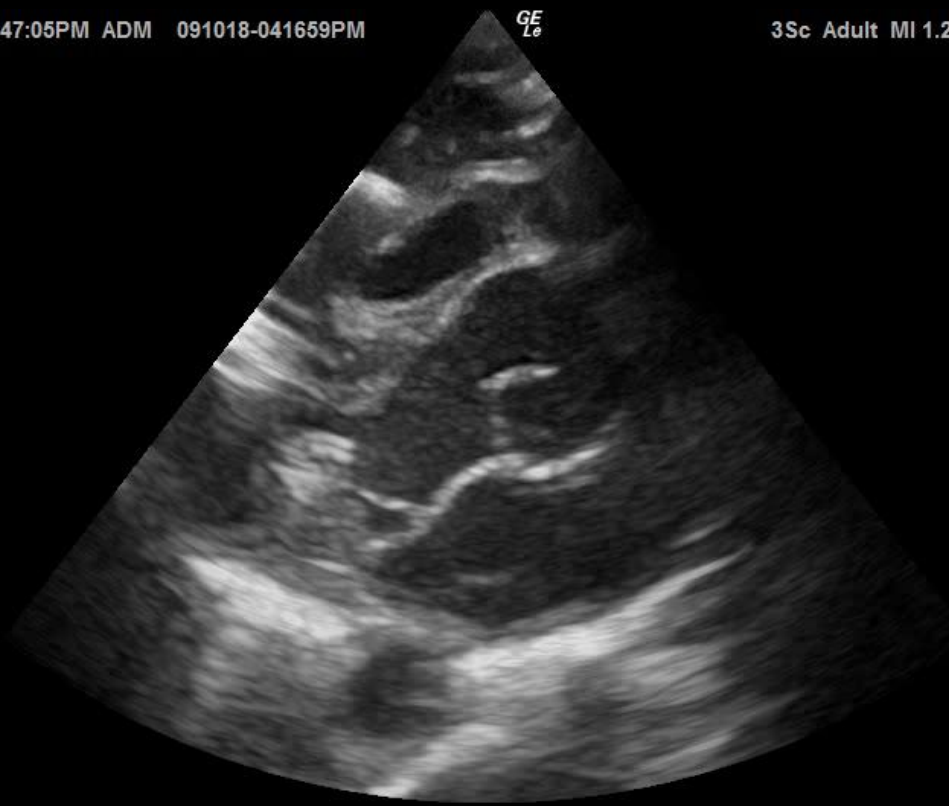
GE  
L<sub>o</sub>

3Sc Adult MI 1.2 TIs 0.3

0-

5-

10-





09/10/18 04:49:23PM ADM 091018-041659PM

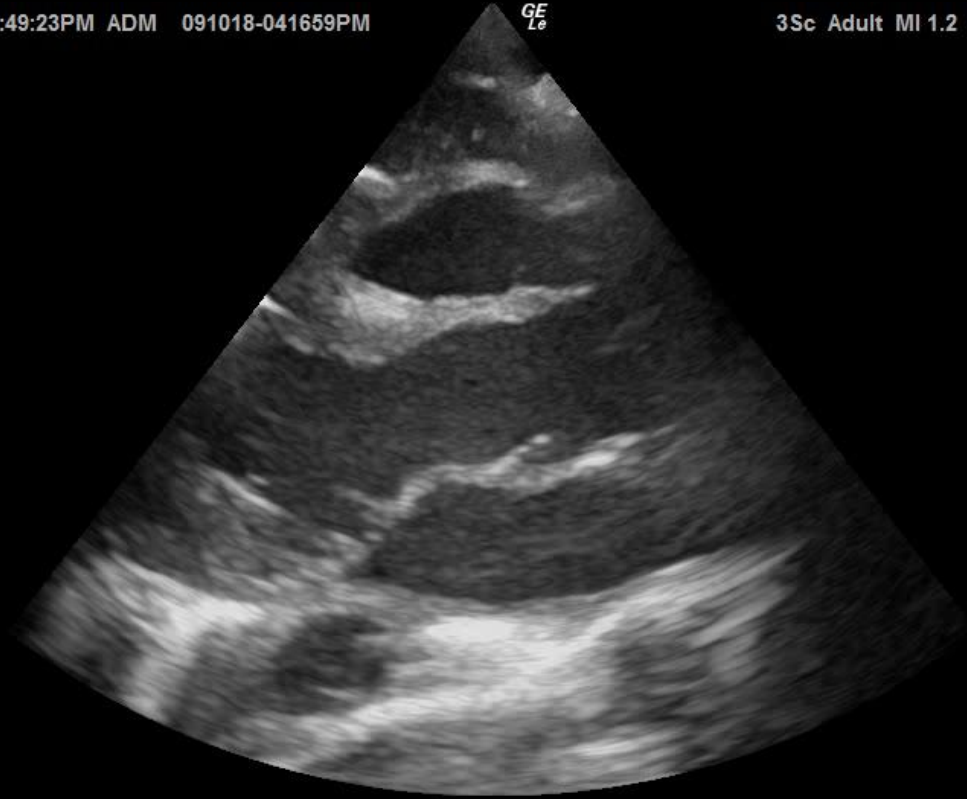GE  
L<sub>e</sub>

3Sc Adult MI 1.2 TIs 0.3

0-

5-

10-



09/10/18 04:49:34PM ADM 091018-041659PM

GE  
L<sub>e</sub>

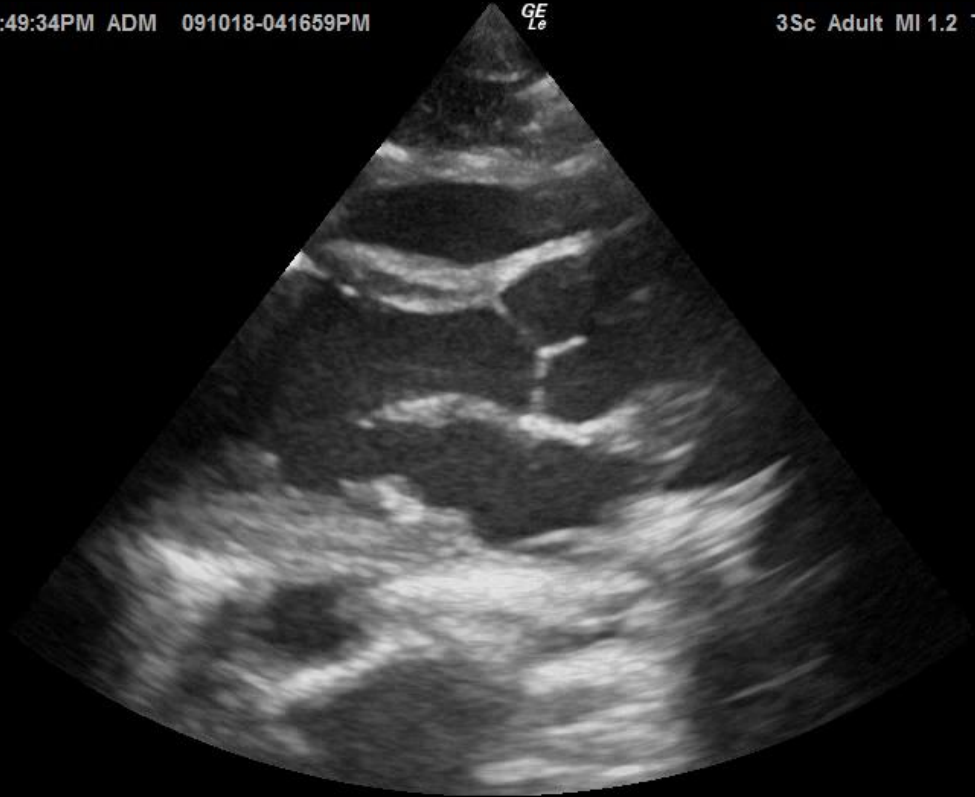3Sc Adult MI 1.2 TIs 0.3

0-

5-

10-

15-

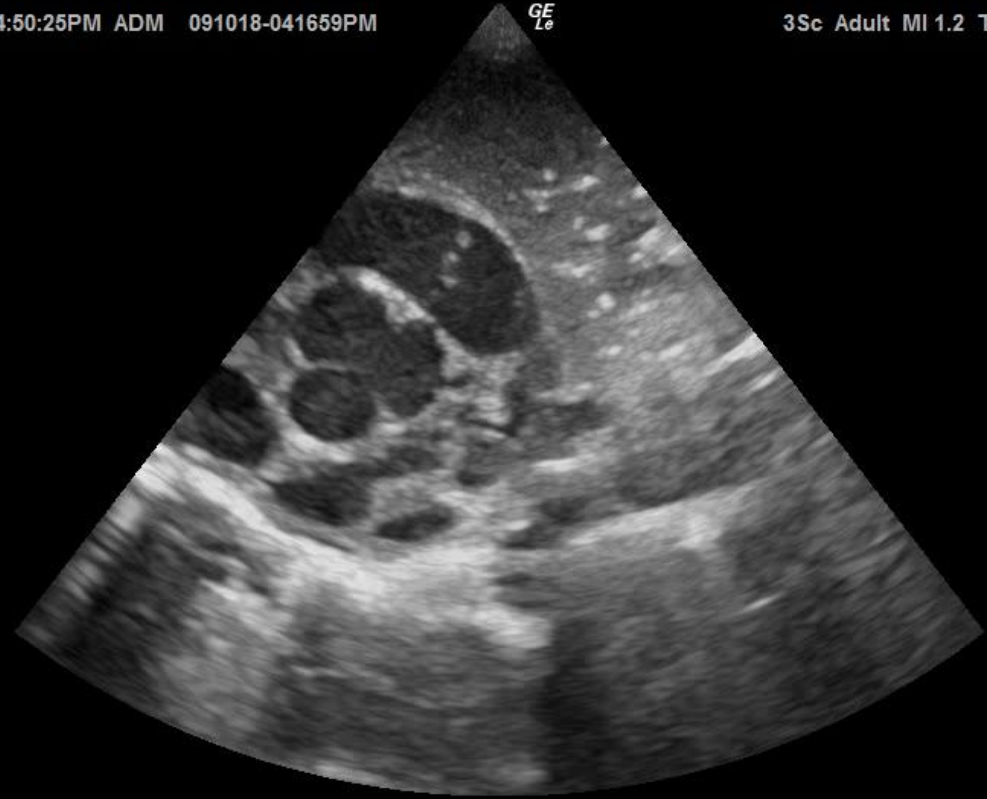

09/10/18 04:50:25PM ADM 091018-041659PM

GE  
L<sub>e</sub>

3Sc Adult MI 1.2 TIs 0.4

0-  
-  
-  
-  
5-  
-  
-  
10-  
-  
-  
15-  
-



09/10/18 04:51:16PM ADM 091018-041659PM

GE  
L<sub>e</sub>

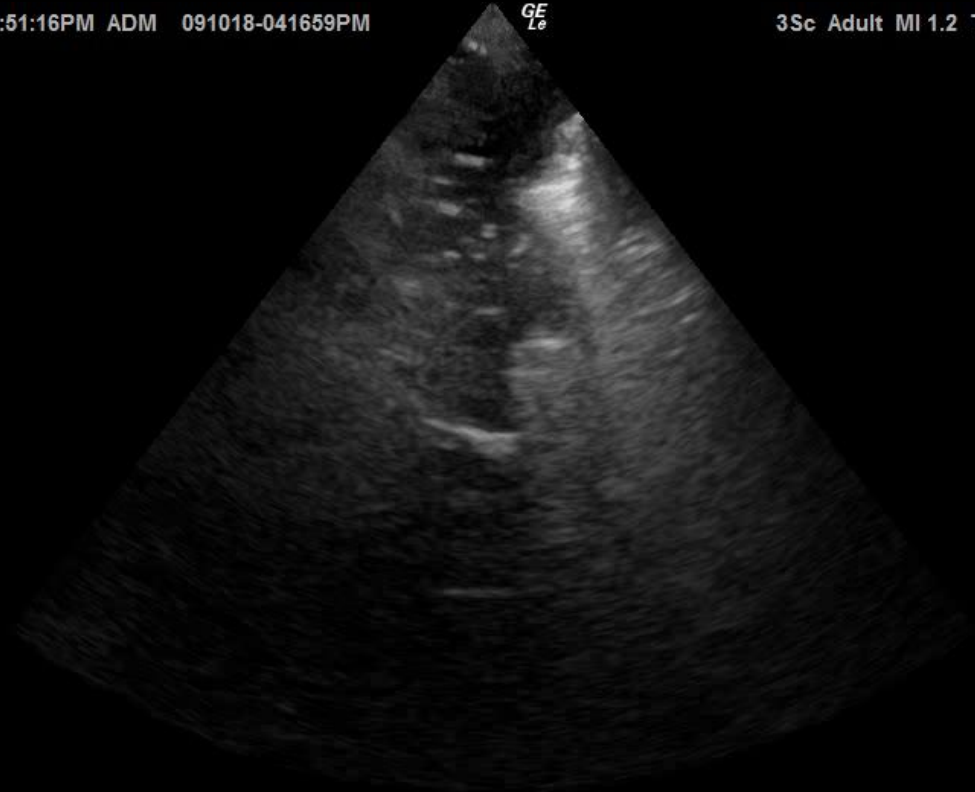
3Sc Adult MI 1.2 TIs 0.4

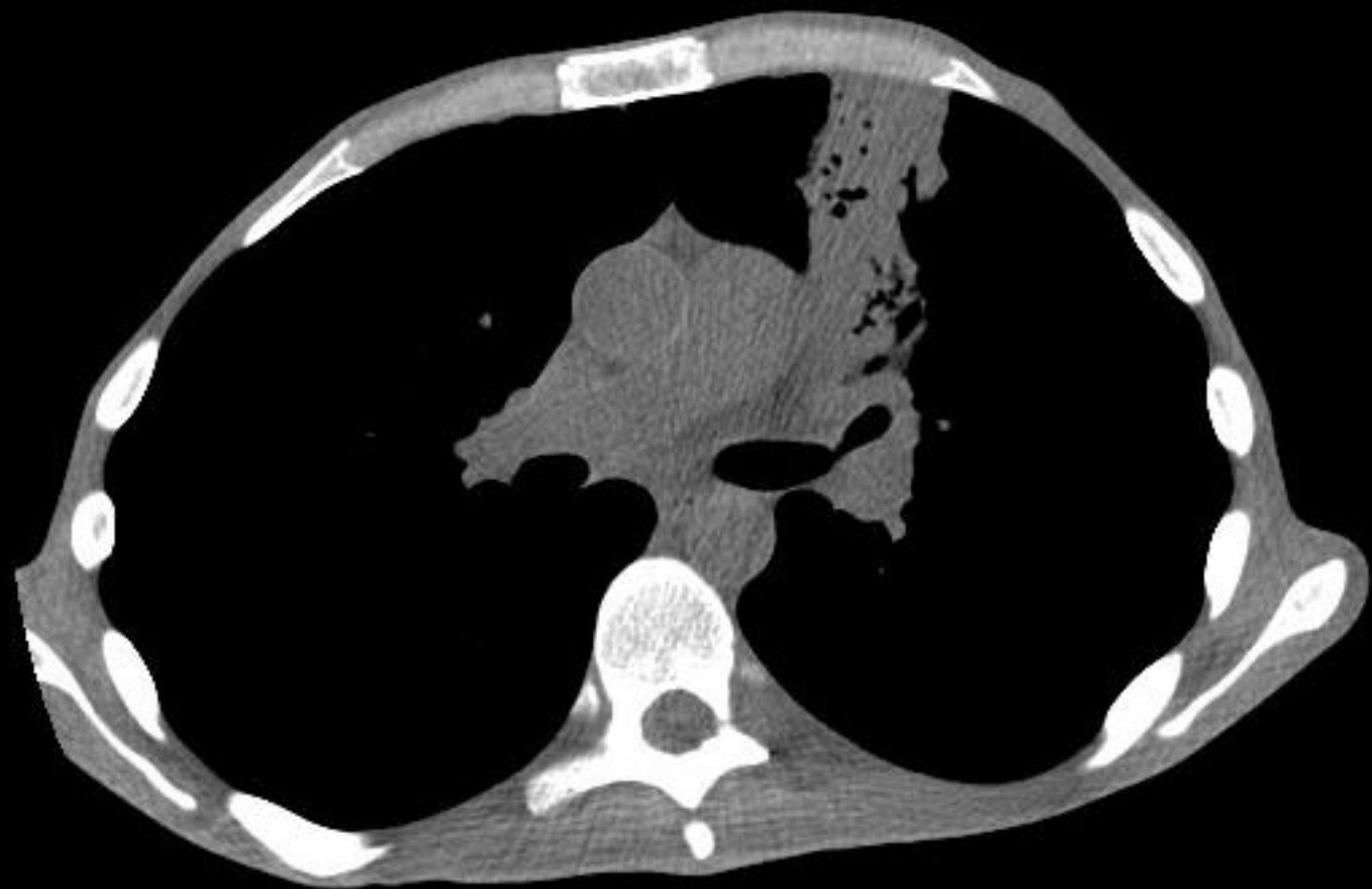0-

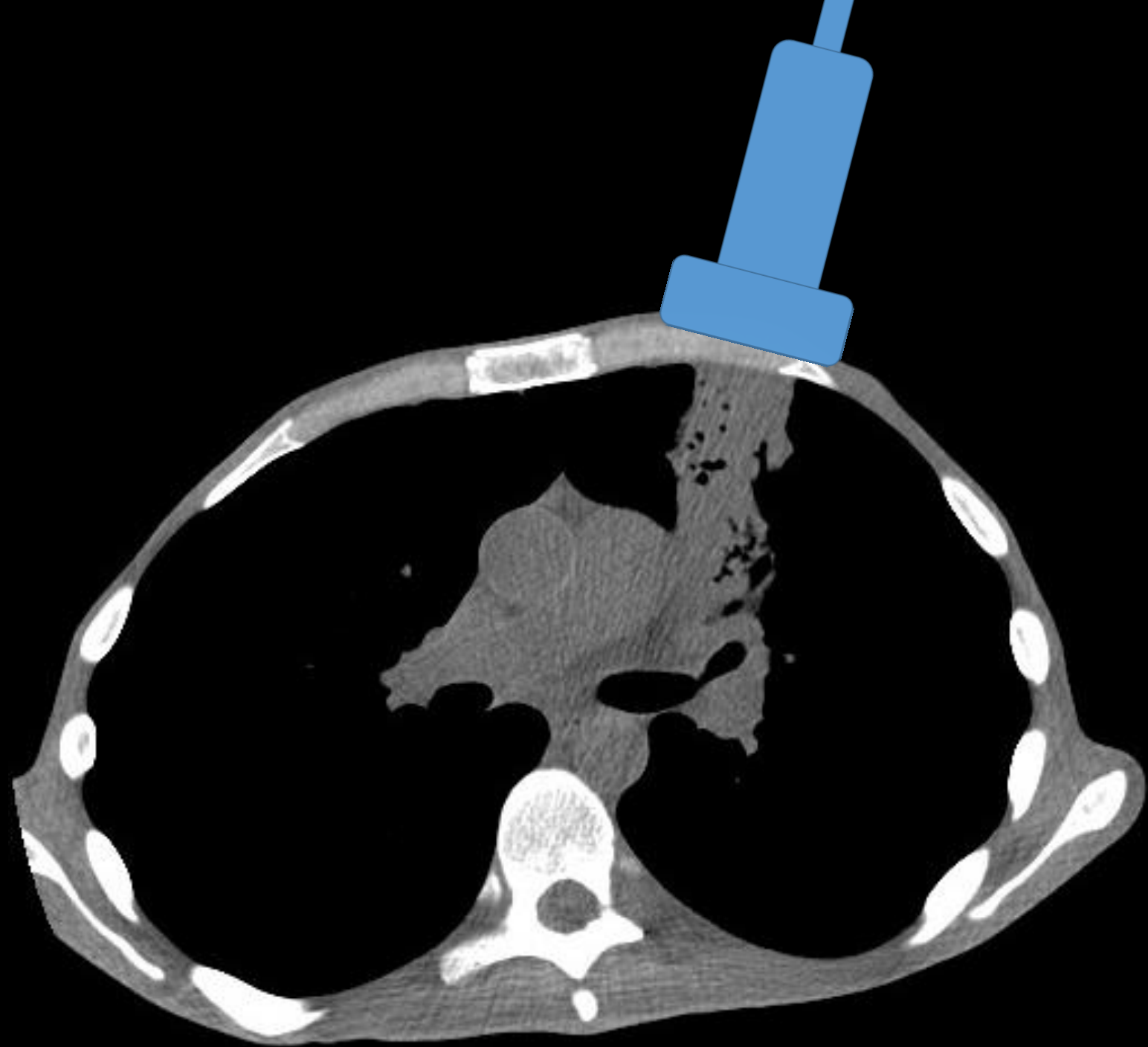
5-

10-

15-







09/10/18 04:56:19PM ADM 091018-041659PM

GE  
L<sub>e</sub>

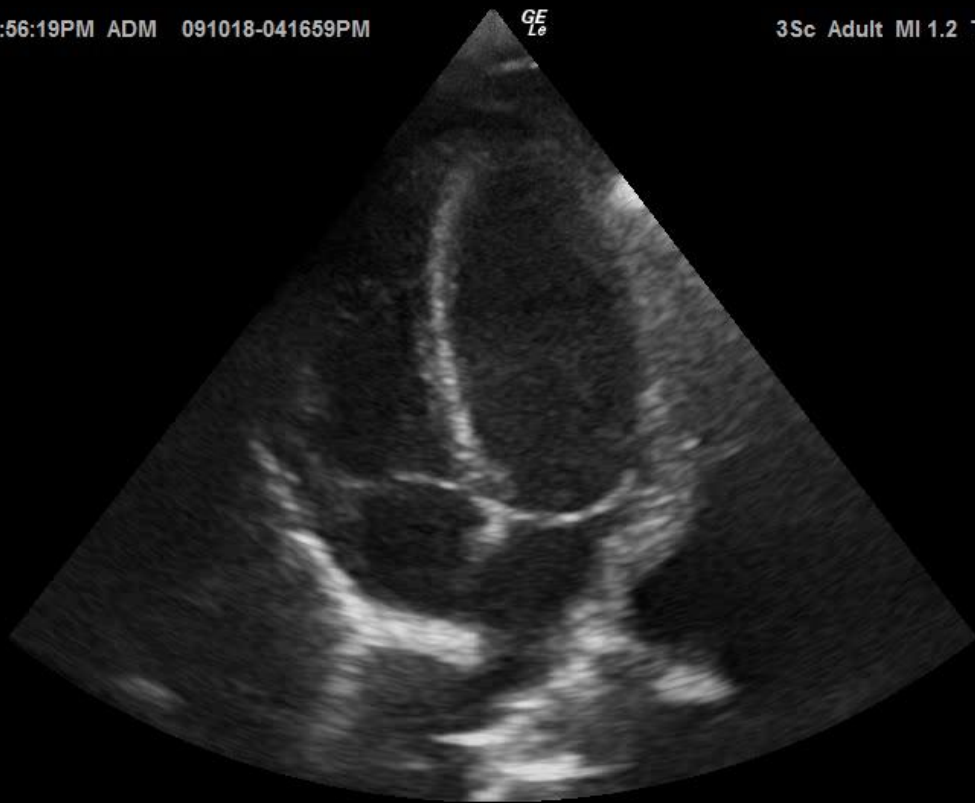
3Sc Adult MI 1.2 TIs 0.4

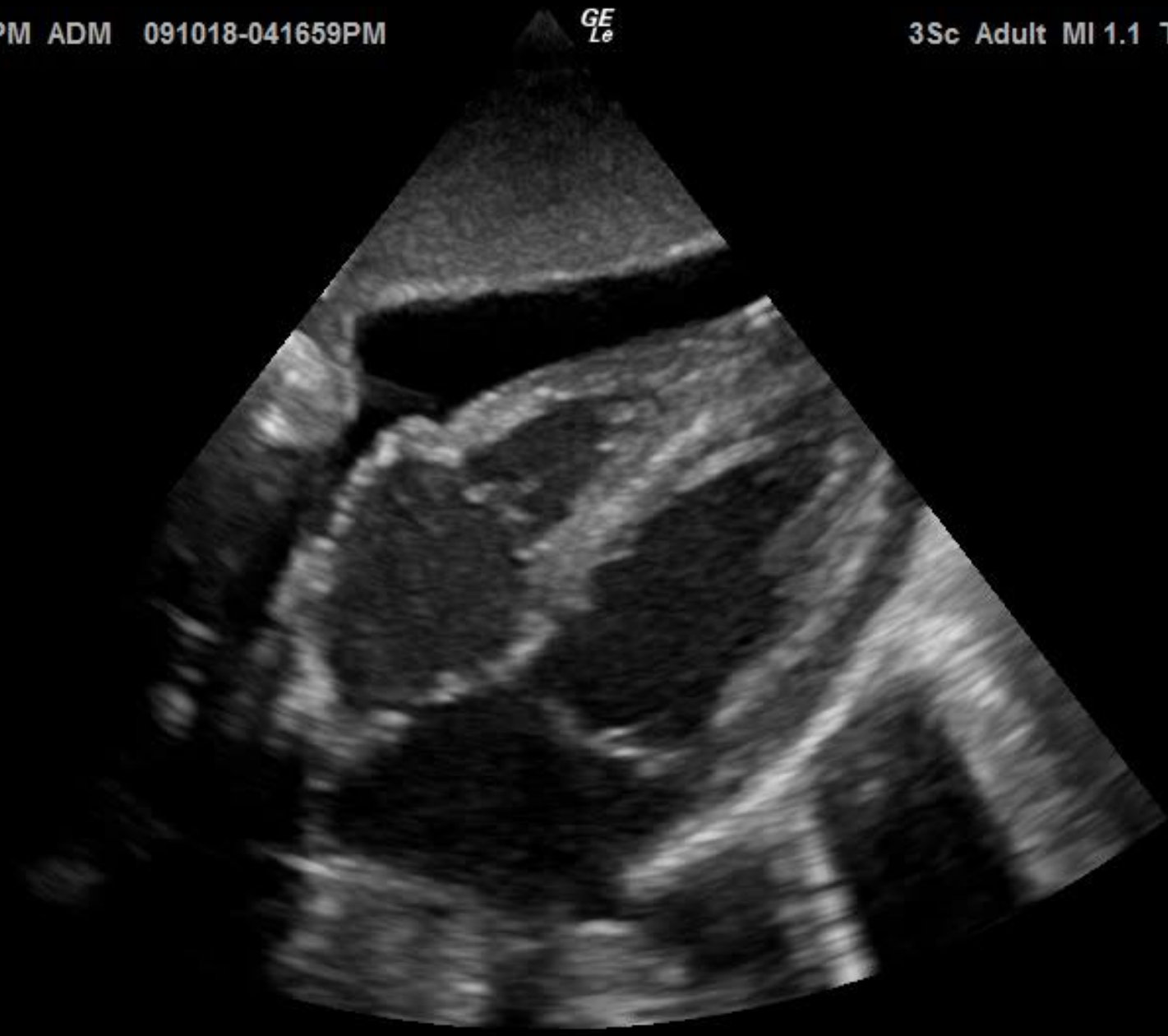0-

5-

10-

15-





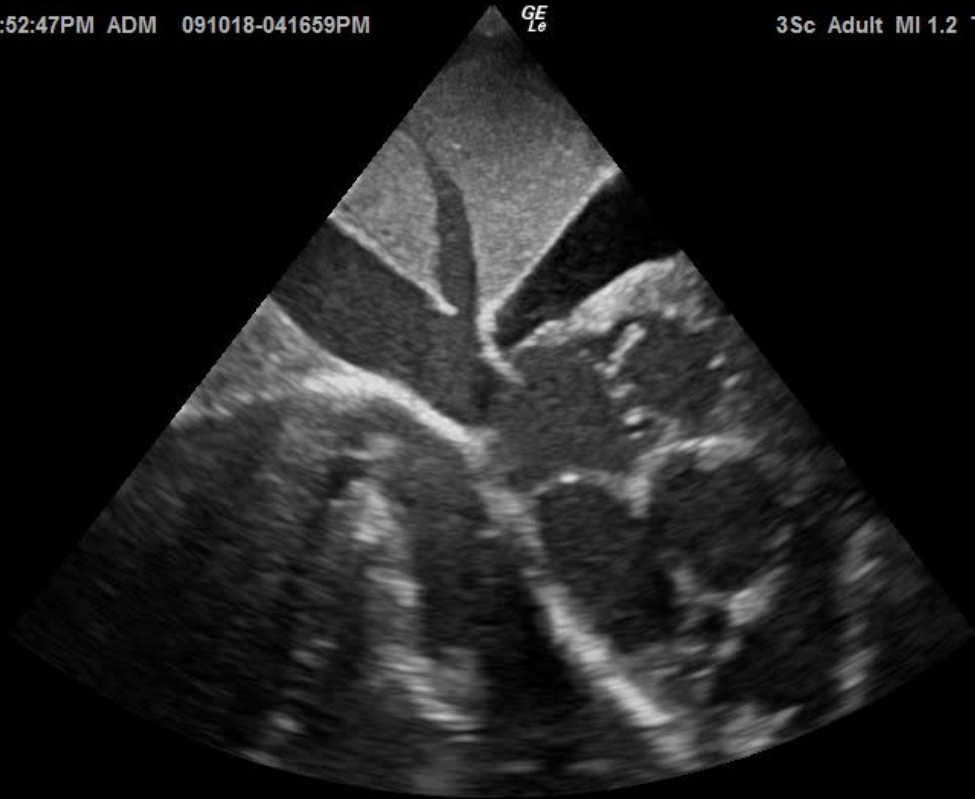

09/10/18 04:52:47PM ADM 091018-041659PM

GE  
L<sub>e</sub>

3Sc Adult MI 1.2 TIs 0.4

U-



10-

M

20-

09/10/18 04:53:22PM ADM 091018-041659PM

GE  
L<sub>e</sub>

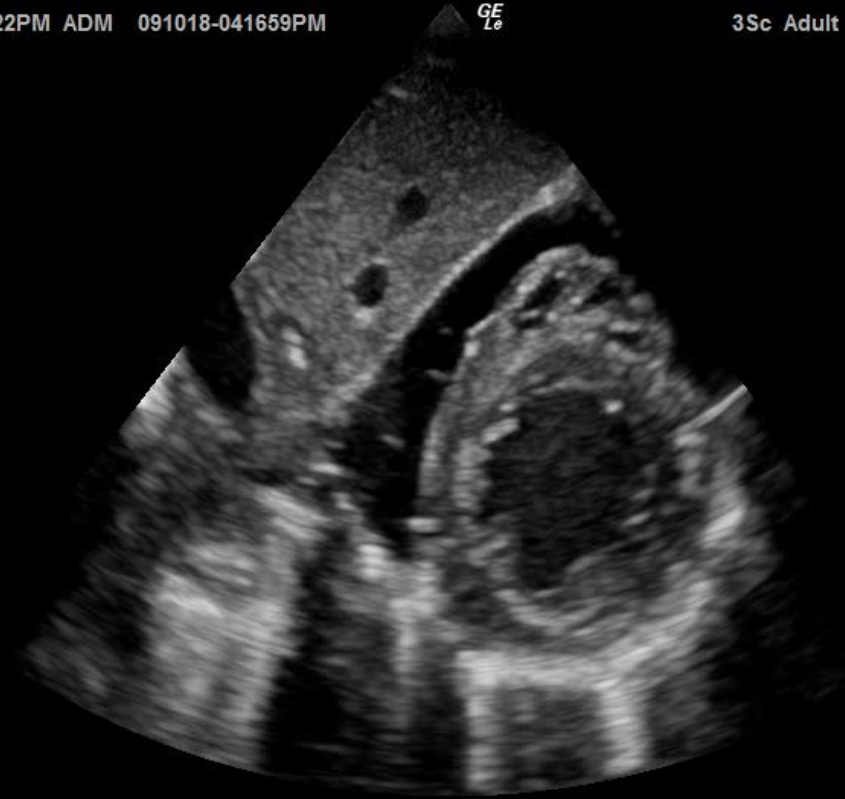3Sc Adult MI 1.2 TIs 0.4

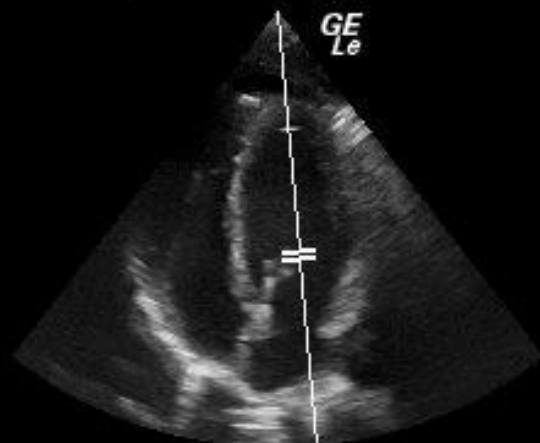
0-

5-

10-

15-





FR	68
AO%	100
CHI	
Frq	3.5
Gn	60
D	18.0
PW	
Frq	2.0
Gn	33
PRF	6.3
WF	100
SV	3
SVD	10.1

