

# POCUS conference

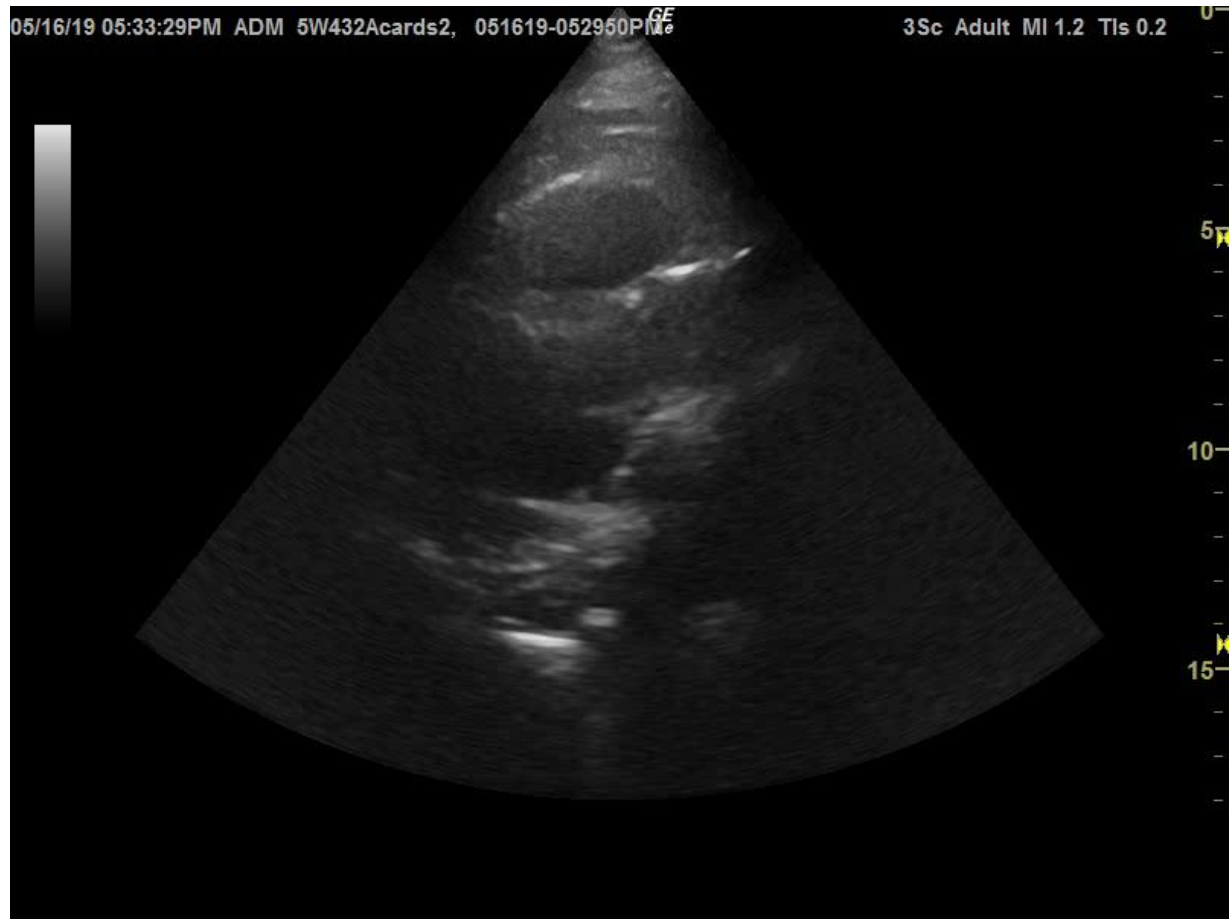Karen Chiu

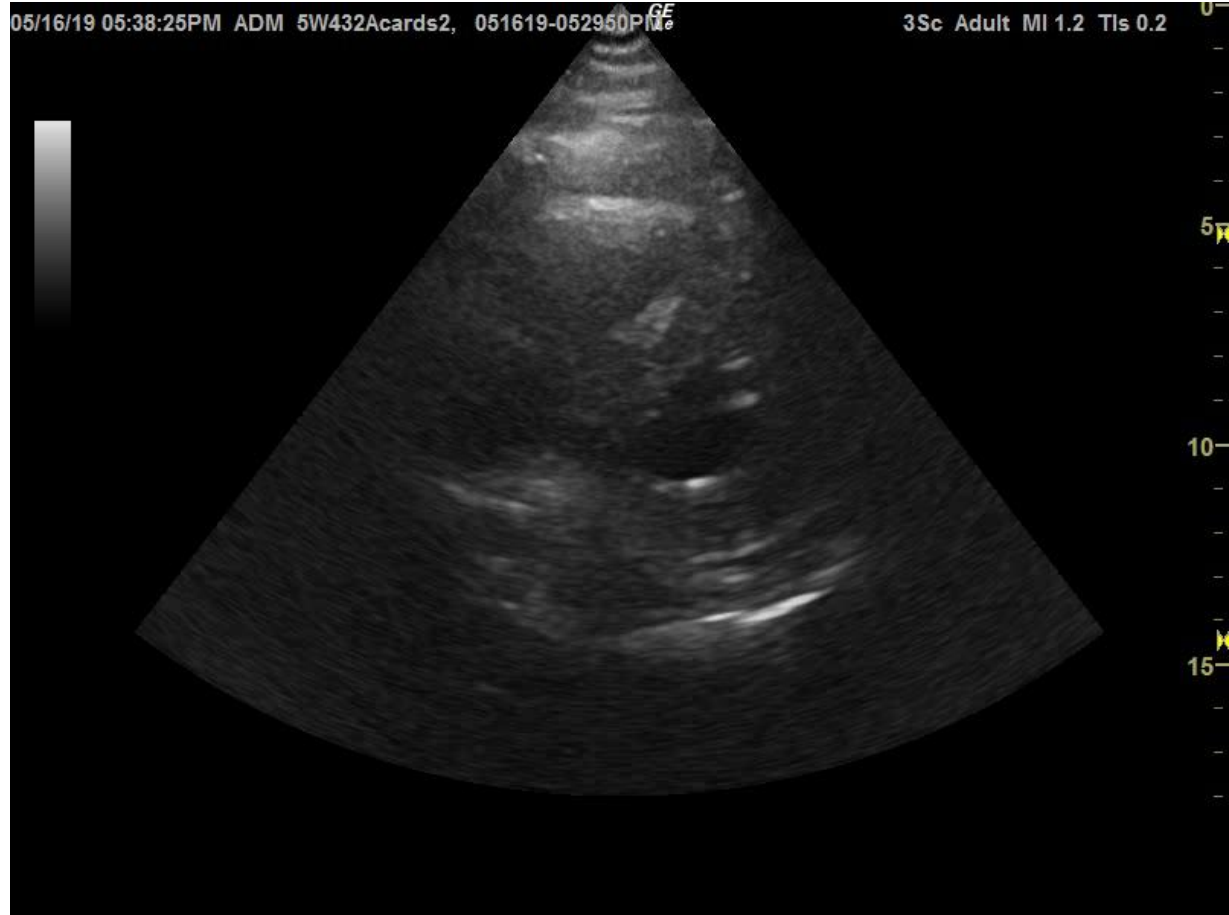5/23/2019

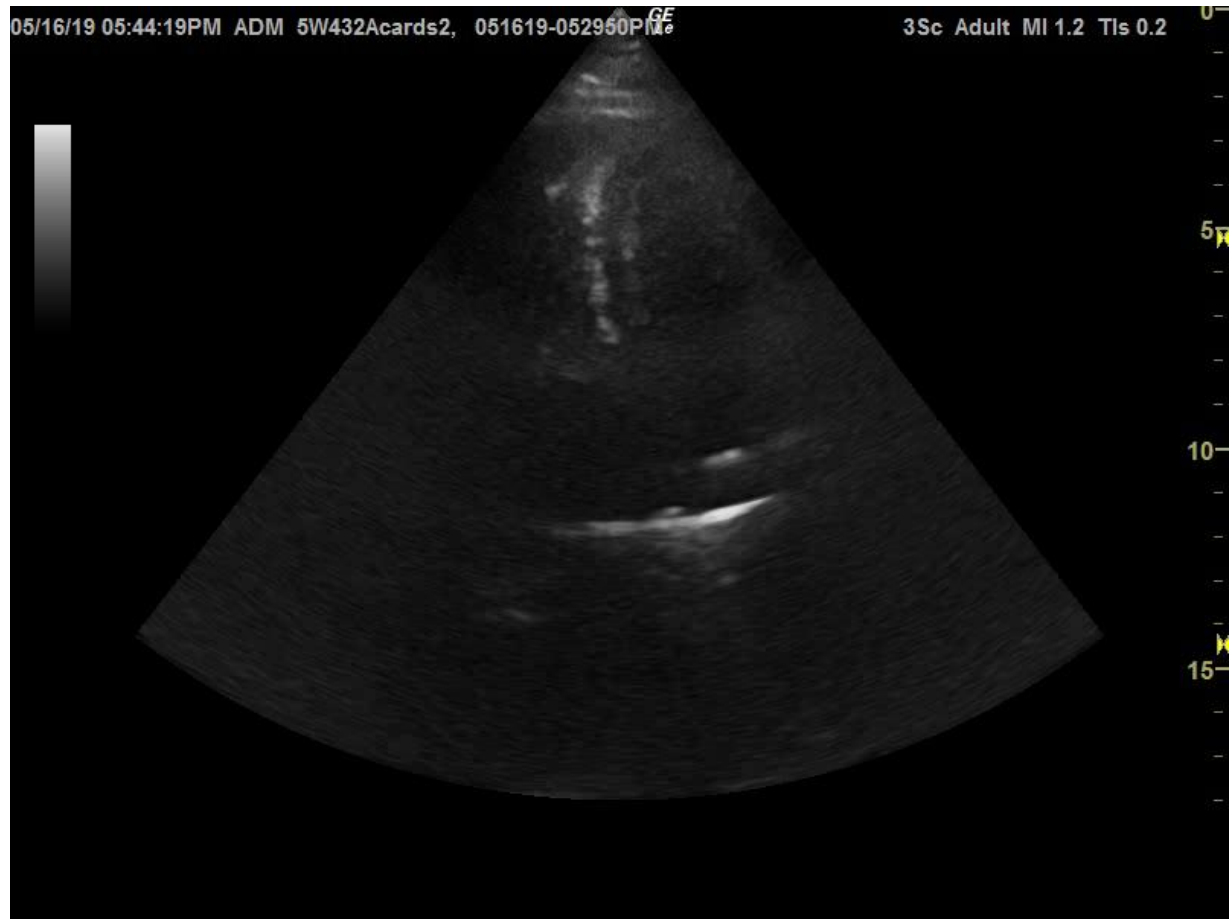# Subacute increasing edema/ fatigue

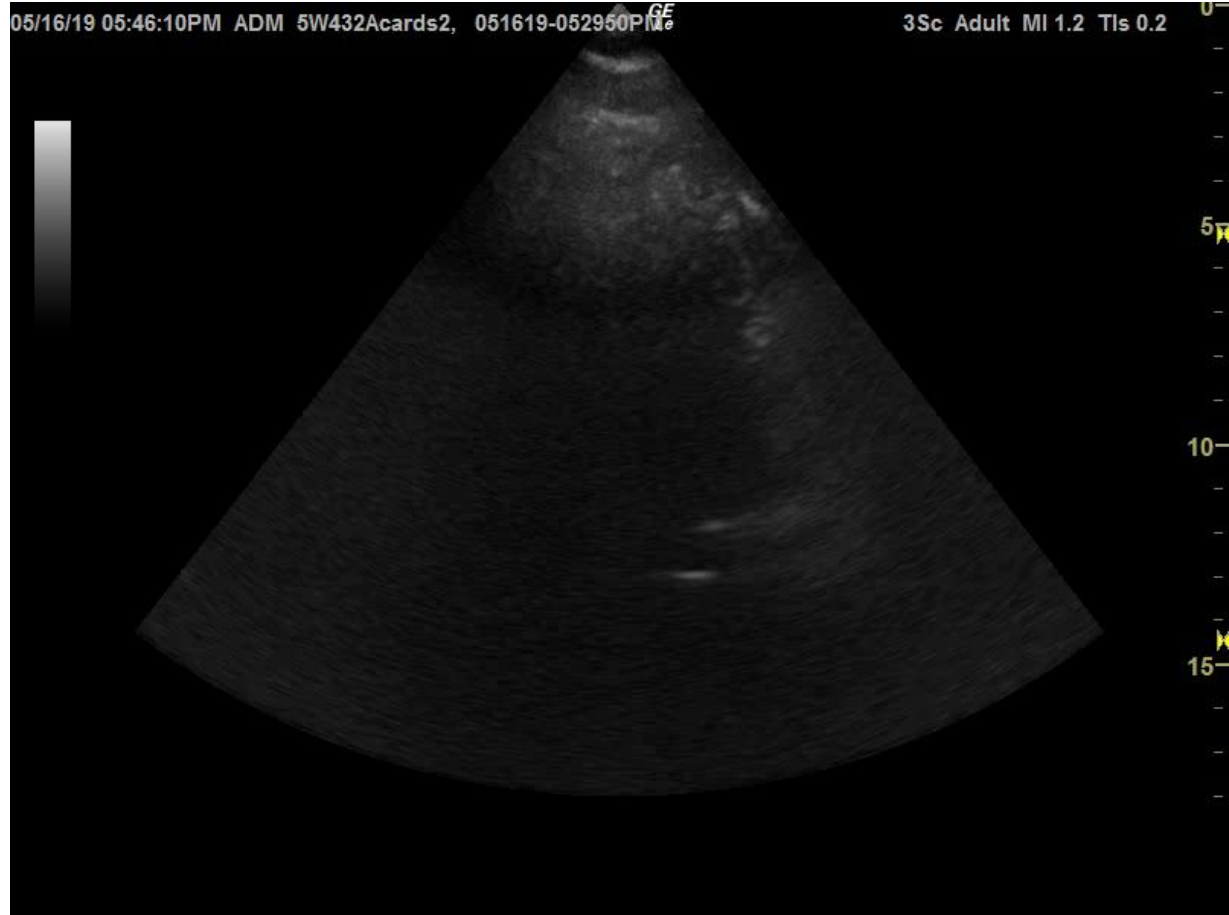- 74YO woman with iCMY (CAD s/p NSTEMI, 2v CABG with 4 stents), MVR on Coumadin, pAF presented for 3-5 weeks of increasing edema, abdominal distension, and SOB.
- TTE 75% in 2017
- Concentric left ventricular hypertrophy.
- Hyperdynamic left ventricular function.
- Normal right ventricular size and function.
- Left atrial dilatation.
- Mechanical mitral valve.
- Non-obstructive prosthetic mitral valve by Doppler.
- Mild aortic stenosis.
- Moderate pulmonary hypertension.
- Thickened pericardium.
- Small pericardial effusion.

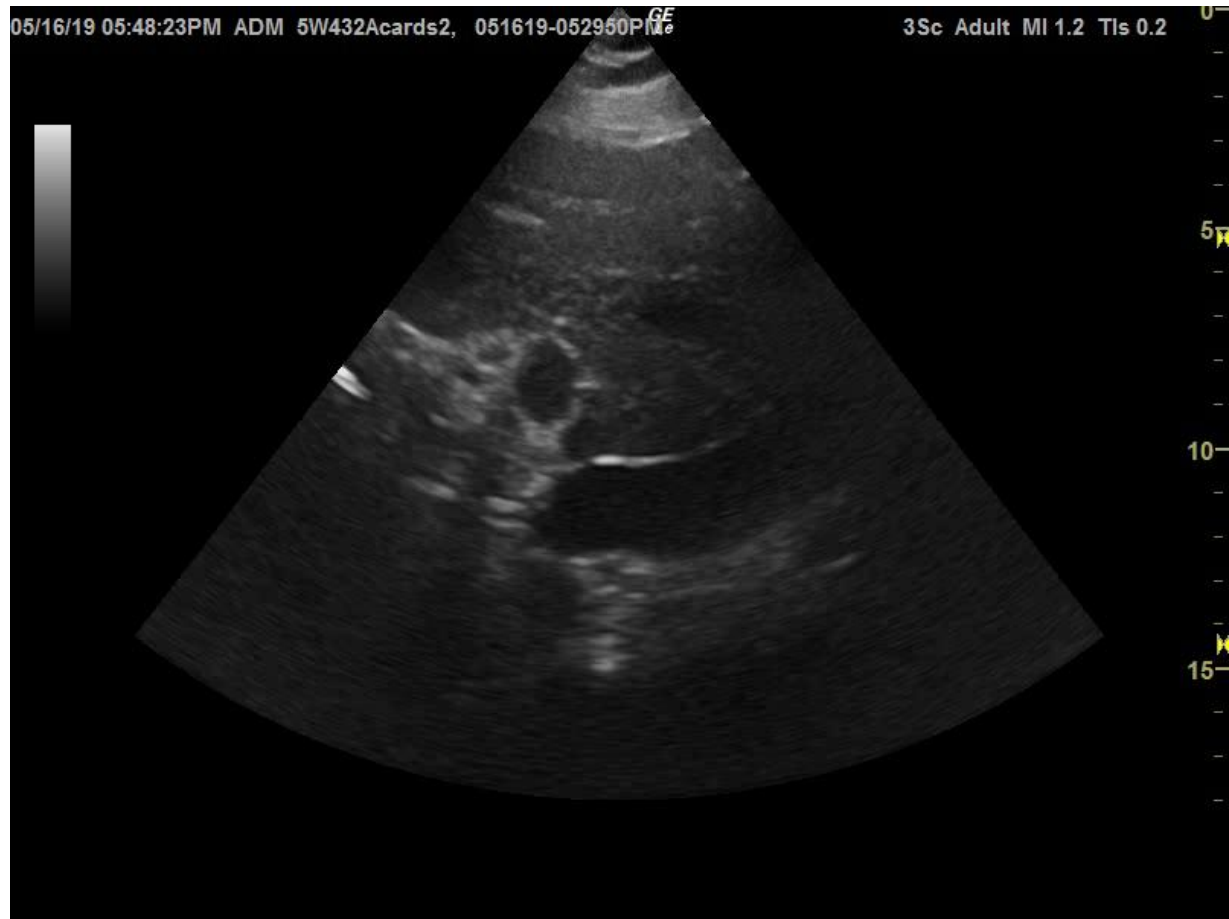- Based on clinical exams, decided to diurese (no home meds for diuresis)
- Started with Lasix 40 BID on 5/8, increased to 60 BID on 5/13
- Weight has decreased from 92.9kg on 5/8 to 81.6kg on 5/16
- 79kg in summer 2016 and 2017, presumably dry weight
- Decided to POCUS to assess fluid status on 5/16



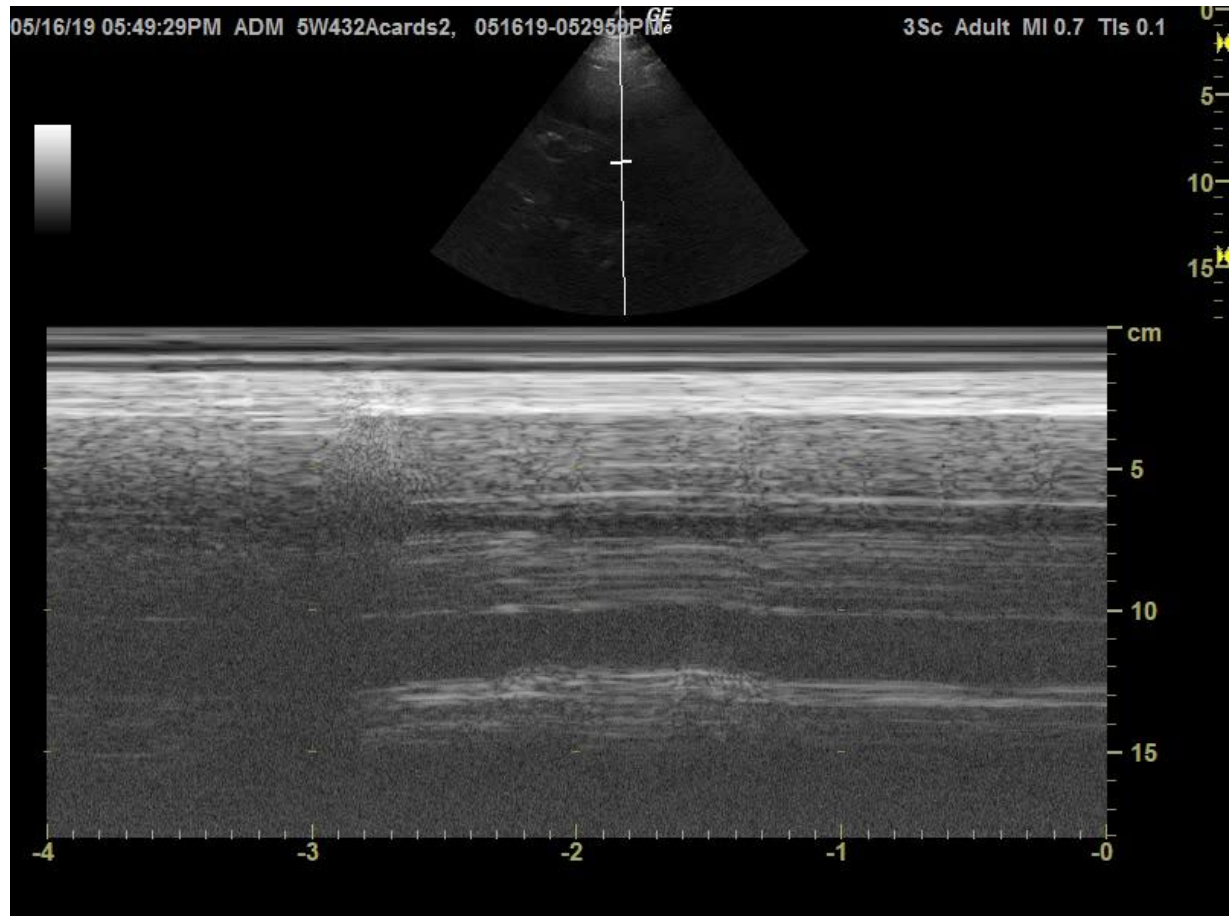


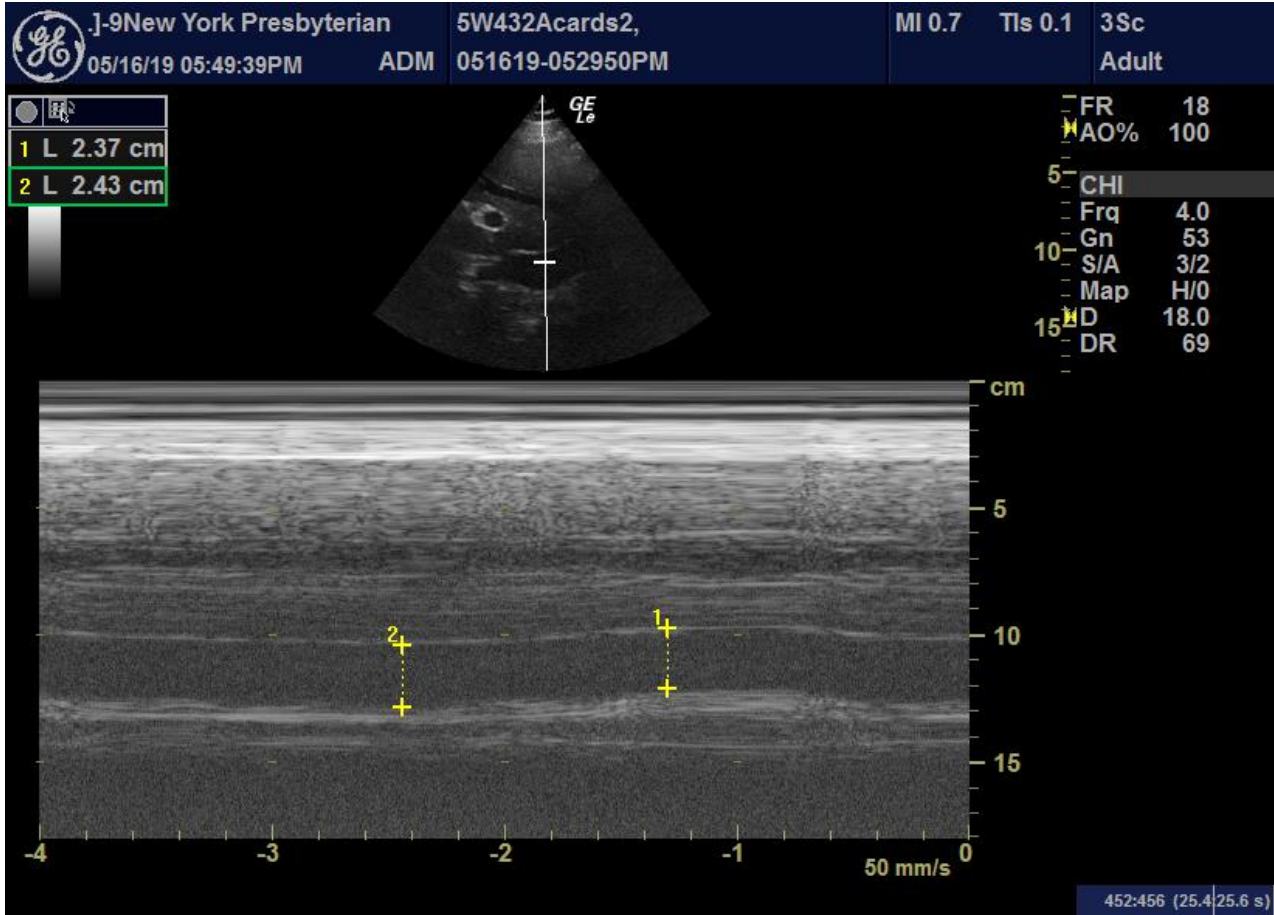


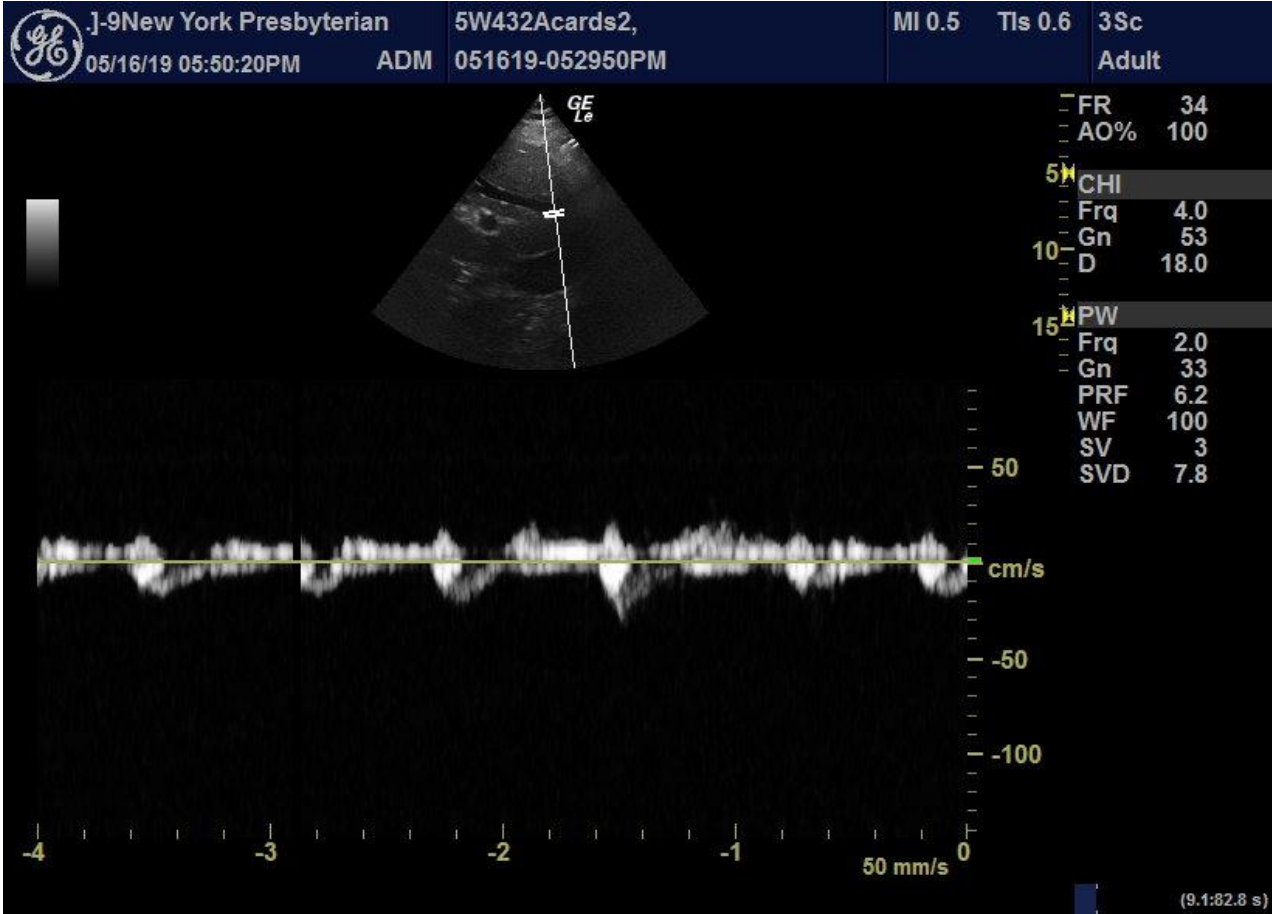


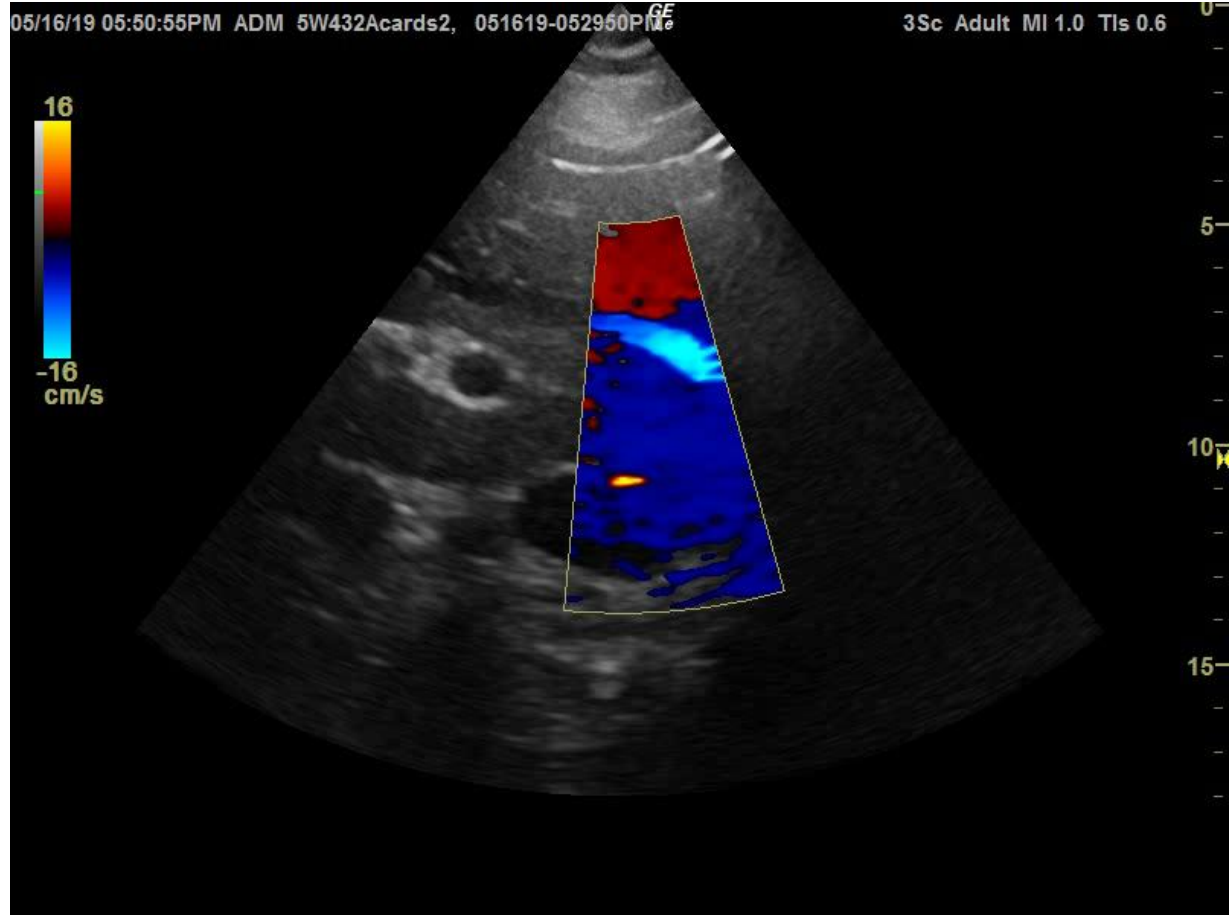


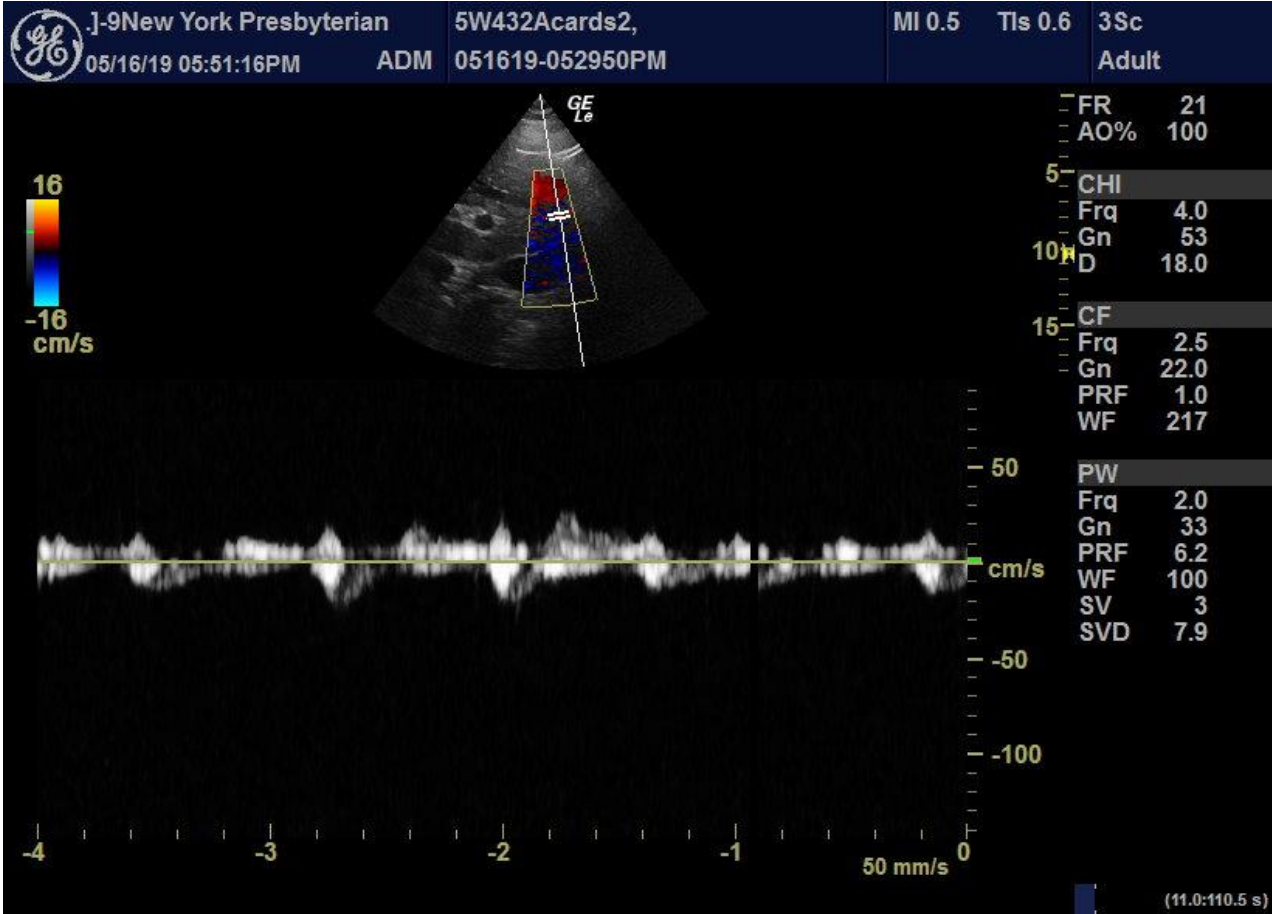


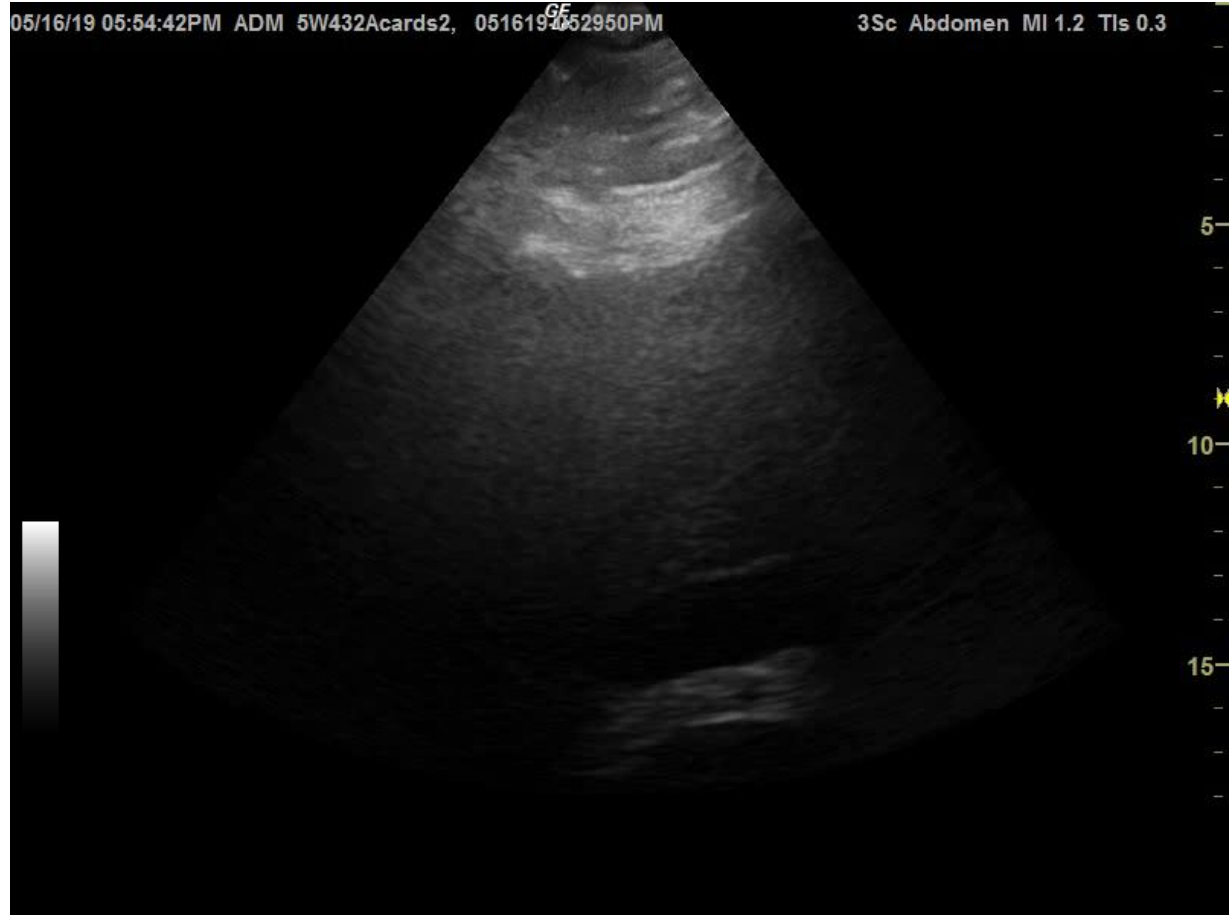


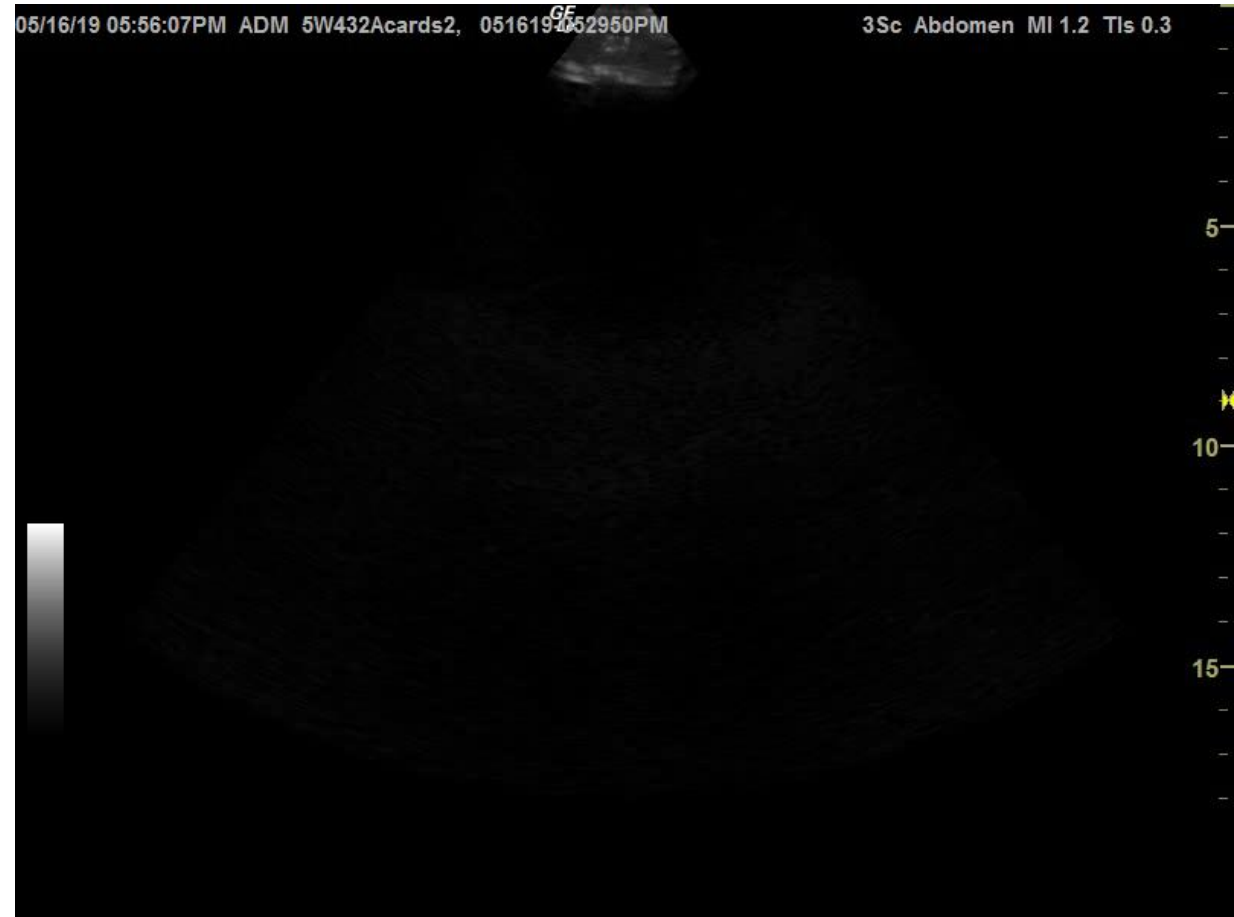


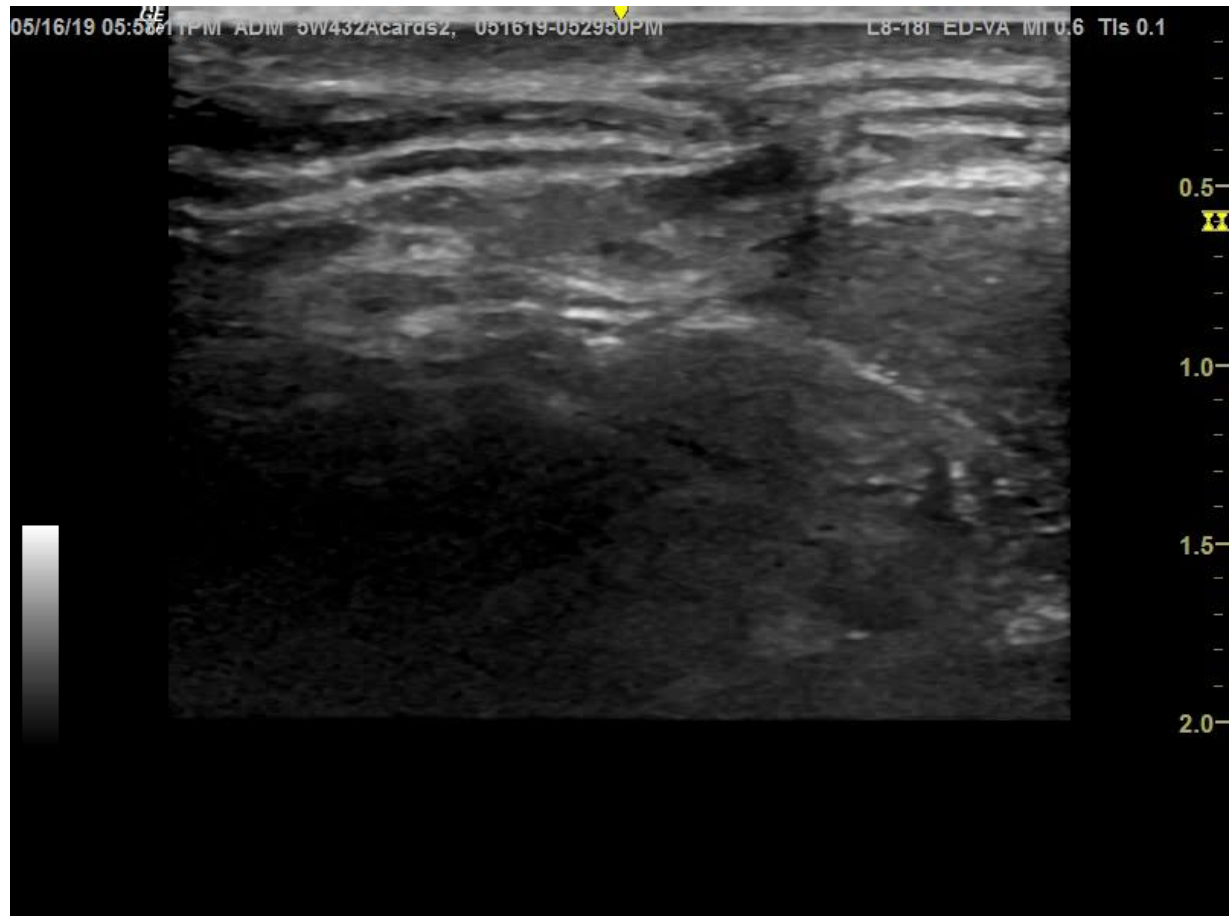











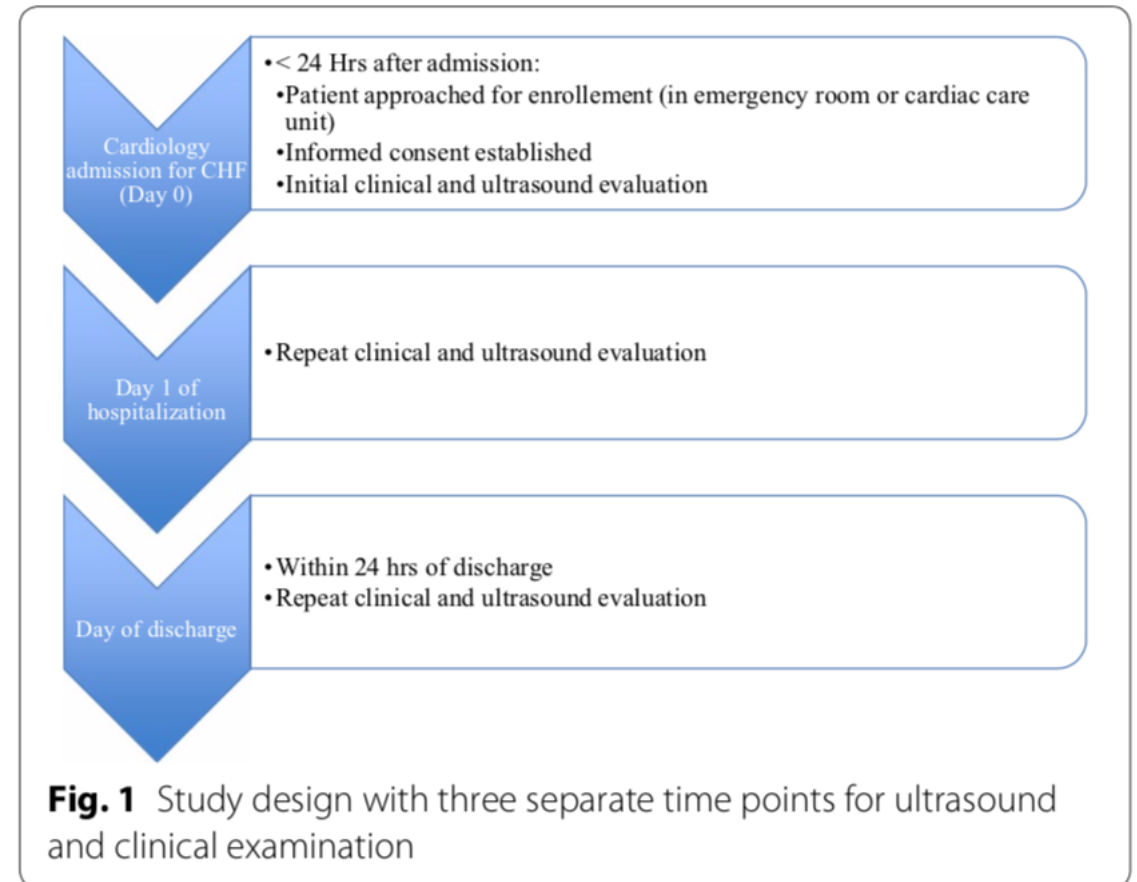
# Decision

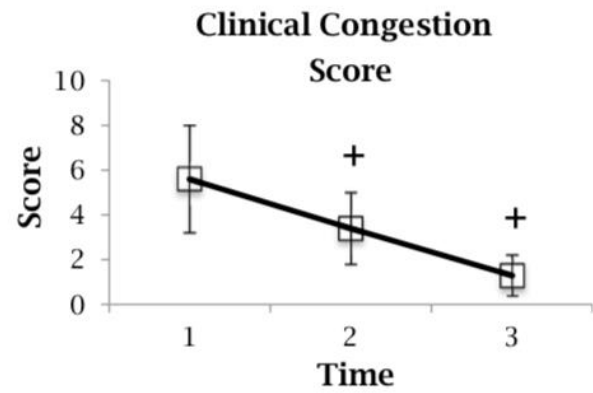
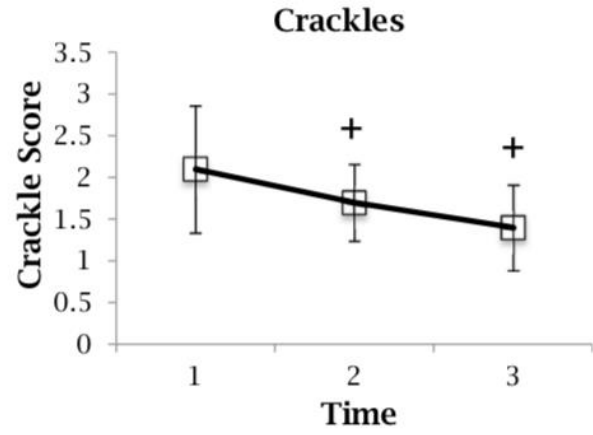
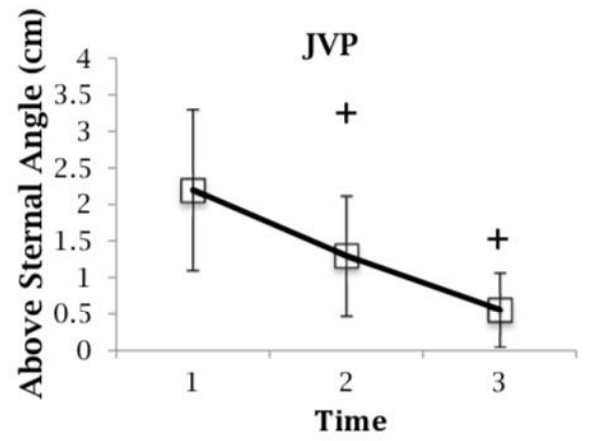
- Increased to lasix 80mg BID on 5/17, then on the day of discharge 5/21 gave an additional dose of metolazone 5mg
- Discharge weight 79.2kg



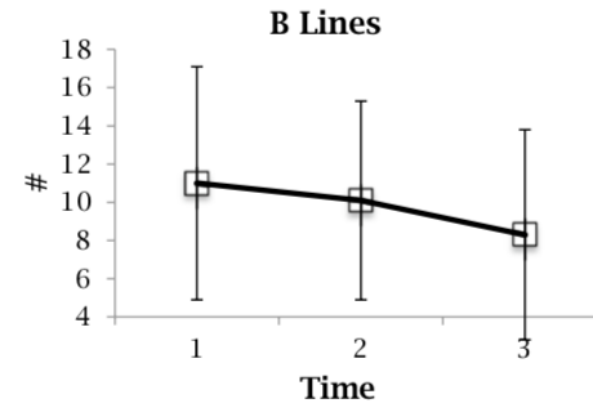
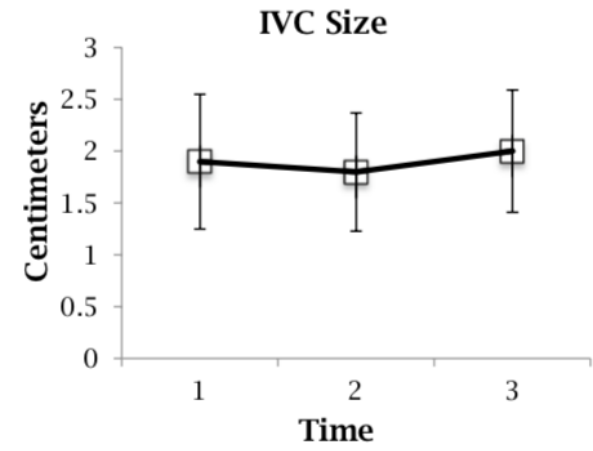
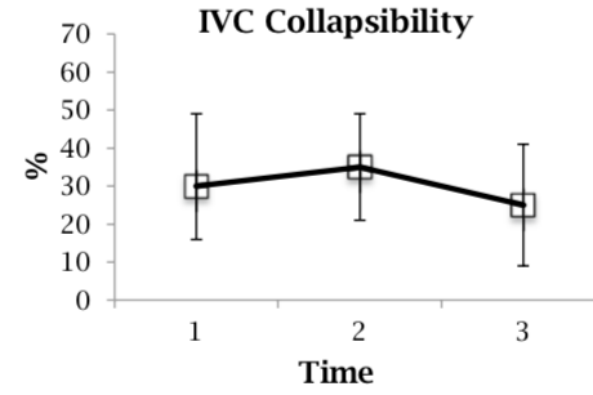
# Serial lung and IVC ultrasound in the assessment of congestive heart failure

Rachel Spevack<sup>1\*</sup> , Mohamed Al Shukairi<sup>2</sup>, Dev Jayaraman<sup>3</sup>, Jerrald Dankoff<sup>4</sup>, Lawrence Rudski<sup>5,6</sup> and Jed Lipes<sup>7</sup>





**Fig. 2** Clinical exam findings at each time point



**Fig. 3** Ultrasound findings at each time point

# Limitations

- small sample size: 50 patients
- treatment initiated while at the ED prior to enrollment during admission; IVC size may have changed prior to first measurement
- median Killip score is 2 (mild heart failure)

# Acknowledgements

- Dr. Cutler
- Dr. Shin
- Patient